

Aesthetic Surgery Journal

<http://aes.sagepub.com/>

Arm Dynamic Definition by Liposculpture and Fat Grafting

Alfredo Hoyos and Mauricio Perez
Aesthetic Surgery Journal 2012 32: 974
DOI: 10.1177/1090820X12461498

The online version of this article can be found at:
<http://aes.sagepub.com/content/32/8/974>

Published by:



<http://www.sagepublications.com>

On behalf of:



[American Society for Aesthetic Plastic Surgery](http://www.asap.org)

Additional services and information for *Aesthetic Surgery Journal* can be found at:

Email Alerts: <http://aes.sagepub.com/cgi/alerts>

Subscriptions: <http://aes.sagepub.com/subscriptions>

Reprints: <http://www.sagepub.com/journalsReprints.nav>

Permissions: <http://www.sagepub.com/journalsPermissions.nav>

>> [Version of Record](#) - Oct 30, 2012

[What is This?](#)

Arm Dynamic Definition by Liposculpture and Fat Grafting

Alfredo Hoyos, MD; and Mauricio Perez, MD

Aesthetic Surgery Journal
32(8) 974–987
© 2012 The American Society for
Aesthetic Plastic Surgery, Inc.
Reprints and permission:
[http://www.sagepub.com/
journalsPermissions.nav](http://www.sagepub.com/journalsPermissions.nav)
DOI: 10.1177/1090820X12461498
www.aestheticsurgeryjournal.com



Abstract

Background: The contour of the arm is determined by muscular shape and volume. Liposuction in this area is challenging due to the difficulties of achieving symmetry and the high risk of contour irregularities due to fat structures in the region.

Objective: The authors describe a new technique to achieve muscular definition in the arm.

Methods: From January 2005 to December 2011, a total of 651 arm-sculpting procedures were performed in consecutive patients. Patients with body mass index (BMI) >30 kg/m² and/or severe skin laxity were excluded. Fat grafting was performed in the deltoid area in selected cases. The areas of fat extraction and grafting were specific to gender: in men, an athletic, muscular look was preferred, whereas in women, a slimmer and less-defined shape was desired.

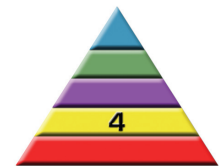Results: Of the 651 patients, 158 were men (24.3%) and 493 were women (75.7%). Most patients (98.3%) were satisfied with the results in arm dynamic definition. All patients underwent other body contouring procedures at the time of arm enhancement. Complications (n = 21) included 1 soft tissue abscess in the posterior arm, 2 unilateral hematomas, and 3 unilateral seromas that required puncture, along with 15 cases of minor asymmetry. Transitory hardening of the skin of the posterior arm was frequent (n = 104) due to superficial fat extraction, but all cases resolved within 6 months.

Conclusion: The authors were able to achieve natural results with this new procedure in arm contouring. The technique is safe and effective with reproducible results when performed through multilayer fragmentation and liposuction with an anatomical extraction. Fat grafting can be performed for contouring with no additional complications.

Level of Evidence: 4

Keywords

liposuction, liposculpture, fat grafting, body contouring, arm liposculpture, ultrasound-assisted liposuction



The arm is one of the most challenging areas in body contouring as a result of the high risk of contour irregularities due to the underlying fat structures in the area (mostly superficial fat), the difficulty of achieving symmetry in this bilateral treatment, the presence of preoperative patient asymmetries, and the thickness of the arm skin.¹⁻¹³ Some authors have described the benefits of skin retraction in arm contouring^{4,5,9,12,13} and the difficulties of arm liposuction^{4-7,9}; others have attempted to establish patient-specific classifications for arm contouring procedures,^{1,10,11} but the lack of a consensus generates a limbo about whether liposuction or brachioplasty is the procedure of choice.^{1,3,10,13}

Arm shape is determined by each patient's muscular disposition and mass. In terms of the underlying structure, 3 main muscles are responsible for the arm shape: the deltoid, tricep, and bicep. However, the general appearance of the arm is very different in men versus women. In men, more pronounced musculature is considered more athletic and healthy, but this type of definition can be considered a disfiguration in women. Slender curves and

toned, smaller muscle masses are considered aesthetically pleasing for women. High-definition liposculpture has yielded an athletic appearance in both genders by shaping the body fat in a multilayer and 3-dimensional approach for contouring, based on the premise of creating concave and convex zones, instead of flattening the areas with liposuction alone.^{8,14} Fat is extracted in some areas but grafted in others to enhance the anatomical architecture. Through emulsification via third-generation ultrasound

Dr Hoyos is an Associate Professor at Universidad de San Martin, Bogota, Colombia. Dr Perez is a plastic surgeon in private practice in Bogota, Colombia.

Corresponding Author:

Dr Alfredo Ernesto Hoyos, Santa Barbara Medical Center, Universidad de San Martin, Calle 99 #9A-80 suite 908, Bogota, Colombia
E-mail: alhoyos@gmail.com

and accurate anatomical aspiration of the superficial and deep fatty layers, an enhancement of the muscular groups is achieved.^{8,11,14-36} These concepts are pillars of the technique we describe in this article.

Many authors have described fat grafting as an option for enhancing bodily contours, including in the buttocks, hands, and face,³⁷⁻⁵⁴ whereas other studies have reported its use in areas such as the female breast.^{44,45,53-59} In breasts, grafting also has been used for reconstruction after oncological procedures with very good results, without changing the incidence in breast cancer.^{33,39,56-58,60-65} Some case reports have shown good aesthetic results with fat grafting to the deltoids.³

ANATOMY

The subcutaneous adipose tissue is composed of 2 layers (areolar and lamellar), which are separated by the superficial fascia. The areolar layer (superficial) is located directly beneath the skin and is composed of fat cells with vertical organization separated by arches of connective tissue (cutis retinacula). It contains blood vessels and lymph vessels. The lamellar layer (deep) is composed of fat cells positioned in an elongated horizontal layout and a large amount of connective tissue forming trabeculae through which blood vessels pass. The deep layer is more prone to store or lose fat whenever a change in diet is made; on the contrary, superficial fat is less prone to changes from diet. To study the local distribution of fatty tissue in the arm, Avelar² divided it into 4 regions: (1) anterior, (2) external, (3) posterior, and (4) internal. In regions 1, 2, and 4, the subcutaneous tissue consists of an areolar layer (superficial) and superficial fascia (without lamellar layer), making these areas less prone to large fat deposits. In region 3 (the posterior arm), there is a distinctive lamellar layer (deep). In patients with increased adiposity, a greater thickness of the superficial fascia and the lamellar layer is observed, compared with the areolar layer. This increase is mainly concentrated in the posterior-external and anterior-external regions, in the upper and middle third of the arm. The posterior arm is also more prone to have skin excess and/or laxity due to the large capacity for fat storage in this area (Figure 1).

Developing a new algorithm for the “ideal” arm for men and women is mandatory. We can see that a well-defined arm in both genders is not flat or straight but has curves. Although the deltoid and the biceps muscles clearly define the curves in the anterior and lateral arm, the contour of the posterior arm is more difficult to define and create due to unique fat distribution. Seen from the side in a 90° position, the athletic posterior arm has curves in the proximal and distal areas. In an ideal arm, the muscle mass of the triceps creates a convex area in the midportion, whereas the triceps tendon flattens the distal posterior arm, and the triceps proximal insertion creates a curvature into the axilla⁶⁶⁻⁶⁸ (Figure 2). This curvature is more acute in men, as their muscle mass is more significant. The inferior border of the arm with the shoulder in

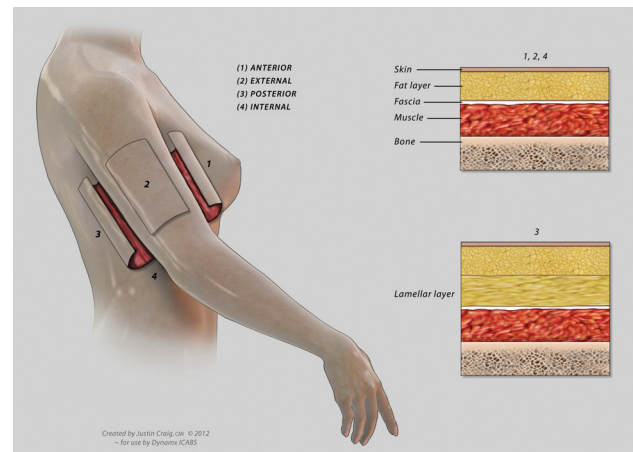


Figure 1. Anatomical basis of fat distribution in the arm according to Avelar²: anterior (1), external (2), posterior (3), and internal (4) zones of the arm. Zone 3 is prone to storing a larger amount of lamellar (deep) fat, which is important in the surgical approach for liposuction.

90-degree abduction defines an angle with a vertical parallel to midline called the “youth angle.” The more acute the angle is, the more pronounced the triceps muscle mass. In obese and older people, the angle tends to be obtuse due to the presence of extra fat and/or skin.⁶⁶

METHODS

We retrospectively reviewed the charts of 651 patients who underwent arm contouring procedures at 1 of 2 centers in Bogota, Columbia, between January 2005 and December 2011. Most patients had excess fat and/or sagging skin on the arm, but patients with severe skin laxity were excluded.

Photographs were taken of all patients for pre- and postoperative assessment. Images were taken from anterior and posterior views, with the arms adduction, at 45°, and 90° abduction. Fat extraction for men was carried out in the deep layer, mostly in the posterior arm and later in the superficial layer in the anterior and posterior muscular landmarks. In women, deep extraction was extended to the entire arm, but the superficial extraction focused on the posterior arm for deltoid definition.

Preoperative Preparation

Patients were preoperatively evaluated, and hemoglobin, hematocrit, white blood cell count, creatinine, urea, and coagulation time were assessed. All patients also underwent acetylsalicylic acid evaluation and consultation with an anesthesiologist. Antibiotic prophylaxis was administered (cefazolin 1 g intravenously [IV] or clindamycin 600 mg IV if allergies to beta-lactamic products were present). Thromboprophylaxis consisted of compression stockings

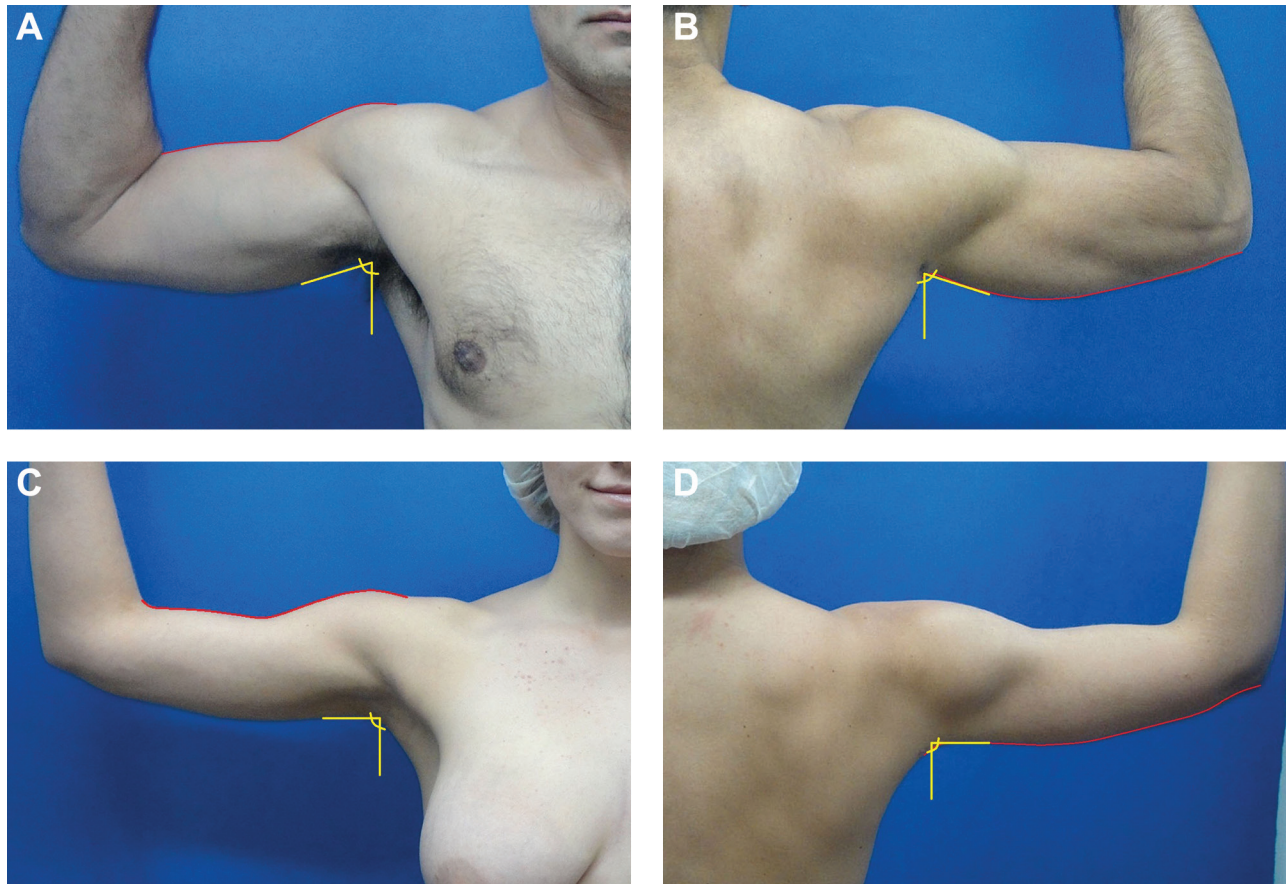


Figure 2. Artistic anatomy of the arm. A 42-year-old man (A, B) and a 29-year-old woman (C, D) are shown. The anterior portion of the arm is defined by the curvature of the deltoid and the biceps (A, C). Due to the presence mostly of superficial (areolar) fat, this area is not prone to changes with weight or aging. On the contrary, the posterior arm is very sensitive to these changes, due to the high presence of deep (lamellar) fat and thin skin that increases in volume with weight changes (B, D). The posterior arm is not straight in its ideal aesthetic form; areas of curvature (negative spaces) are present in the proximal and distal arm, due to the triceps tendon (distal) and the insertion of the proximal triceps. The angle between a vertical line and the proximal posterior arm is defined as the “youth angle” (yellow lines). This angle should be 90° or less.

applied to the lower limbs and low molecular weight heparin administration (enoxaparin 1 mg/kg/d). A single intravenous dose of 8 mg dexamethasone, 8 mg ondansetron, 75 mg diclofenac, and 50 mg tramadol was administered to each patient during the surgical procedure. To preserve the patient’s body temperature, heated intravenous fluids and a thermal blanket were also used.

Markings

Patients were preoperatively marked in the upright position. Different markings were made for men versus women (Figures 3 and 4).

Men. First, the areas of visible extra fat were marked with the arm in adduction; these areas were mostly in the posterior area. Depending on the patient’s biotype (fat, slim, athletic), the area was marked for deep extraction or more superficial liposuction to create the triceps curvature. Visible extra fat was also marked in selected patients in the inner or anterior portion of the arm as needed.

After that, 3 muscles were marked: deltoids, biceps, and triceps. We asked the patient to place his or her arm in 90° of abduction with 90° of elbow flexion and internal rotation of the shoulder, to mark the posterior sulcus of the deltoid (contraction mark). Later, with the shoulder in external rotation, we marked the anterior sulcus. Then,

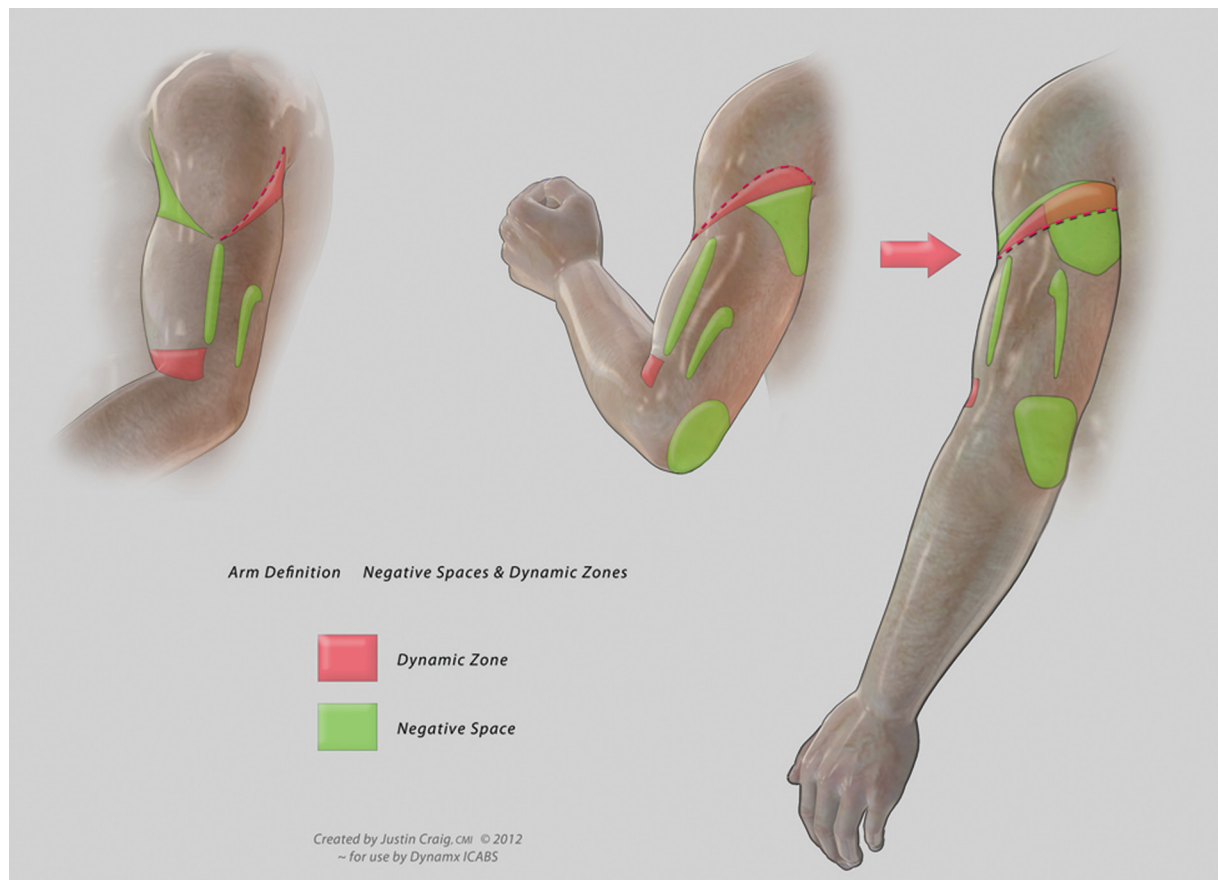


Figure 3. Areas to be marked for arm definition in men. Negative spaces include the bicipital groove (internal and external), the tricipital tendon, and the posterior border of the triceps in the proximal and distal portion. Notice that the zones of dynamic movement are treated as zones of negative space in the area of the posterior deltoid sulcus and the distal bicipital tendon. These markings move as different muscles contract, so for accuracy, a transition zone is outlined in these areas.

with the patient's upper arm in complete adduction, we asked the patient to make a voluntary contraction of the triceps muscle and placed a second mark in the deltoid posterior sulcus; between the first deltoid contraction mark and this one, a zone was established. This was called the "dynamic zone." In active contraction of the triceps, another mark was done at the muscle in the inter-fascicular zone. The bicipital groove was marked internally and externally. Marking the biceps in contraction at 90° of flexion of the elbow, we outlined a semilunar zone from the distal muscle tendon to the crease of the elbow, another dynamic zone.

Women. Marking the arm in women was easier than marking the arm in men. With the patient's arm in adduction, the excess fat was marked; in some women, fat deposits were located in the internal portion of the arm, and these were marked with the arm in abduction.

Later, with 90° of arm abduction, 90° of elbow flexion, and internal rotation of the shoulder, the posterior deltoid sulcus was marked and a triangular, "hollow" area was marked between the axillary posterior crease and the proximal posterior insertion of the deltoid

muscle. In women, the triceps is not marked, as the ideal female arm does not have significant muscle mass in that area.^{66,68}

Surgical Technique

General anesthesia was administered in most patients; only 5 cases in which the arm was the only area being treated were done under local anesthesia. The patient was placed in the prone position, with 90° of arm abduction and 90° of elbow flexion. Three 5-mm incisions were made at (1) the posterior axillary crease, (2) the anterior axillary fold, and (3) in the elbow, at the olecranon tip. In women, usually only 2 incisions were made—at the posterior axillary crease and the olecranon tip—with the exception of obese women, in whom the anterior axillary fold incision was also made.

Tumescent solution was used to uniformly infiltrate the layers of fat, starting in the deep layer and ending in the superficial layer. The solution consisted of 1000 mL of normal saline and a vial of 1:1000 epinephrine. The ratio of infiltration to suction was 2:1.

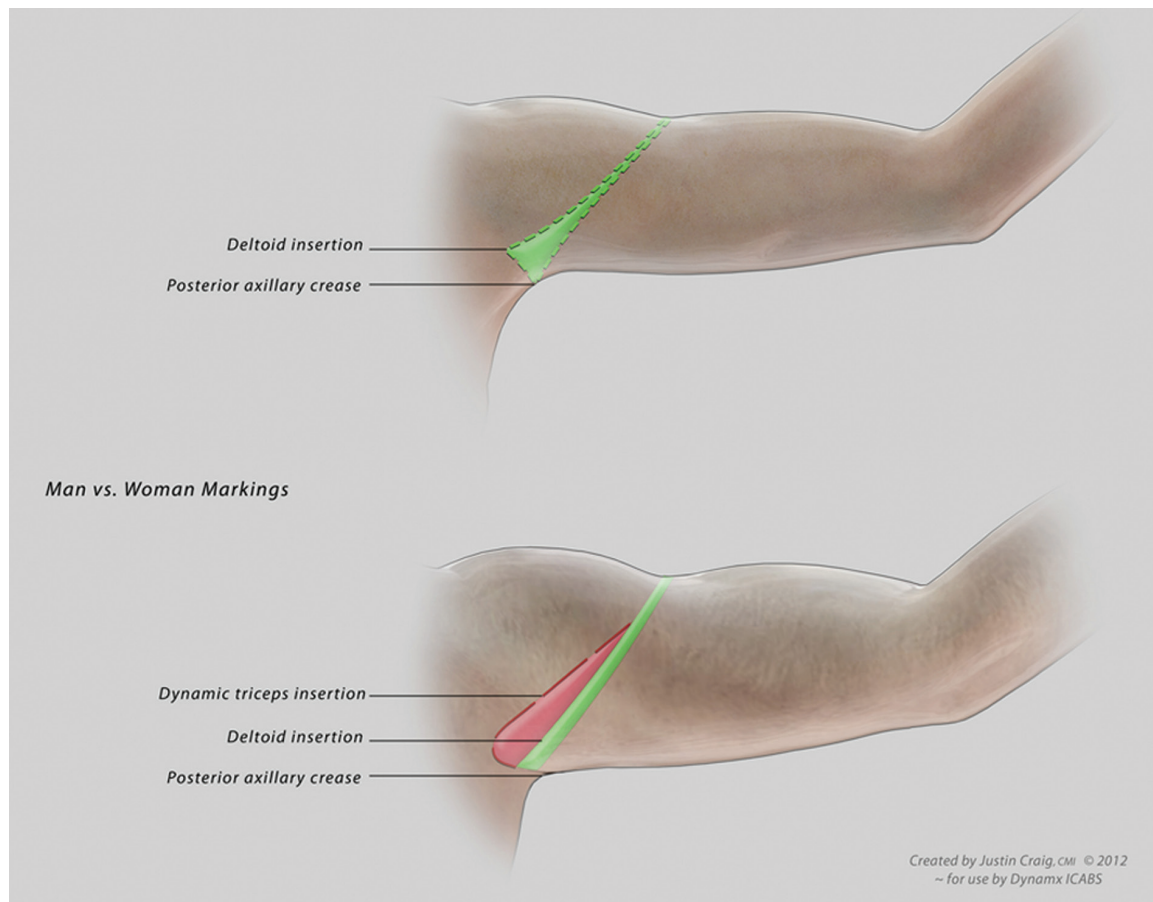


Figure 4. Markings based on patient's gender. The deltoid posterior sulcus is defined in women as a negative space between the sulcus and the posterior axillary fold; in men, due to the larger muscle mass of the triceps, the negative space moves proximal according to the position of triceps contraction.

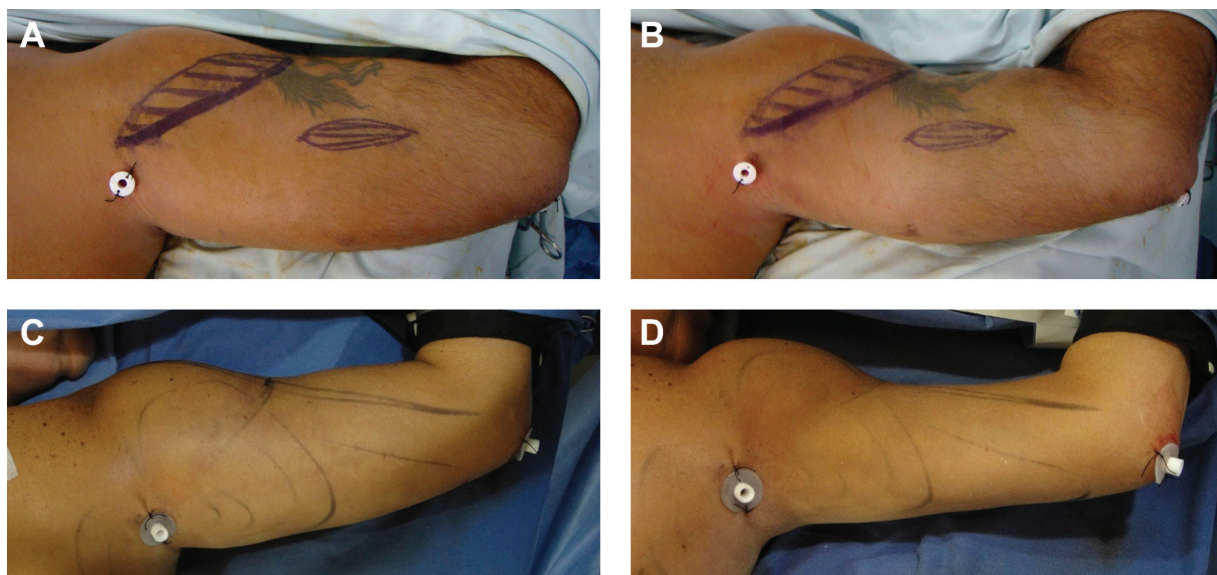


Figure 5. A 34-year-old man is shown (A) preoperatively and (B) immediately postoperatively. A 31-year-old woman is shown (C) preoperatively and (D) immediately postoperatively. Both patients underwent the arm contouring procedure described by the authors in the main text. In the postoperative images, a change in shape and volume can be noticed, including curved posterior areas at proximal and distal ends. Also, the curve of an indentation at the deltoid sulcus is visible in both patients, but the fat resection in the man was less aggressive in the midportion of the posterior arm to avoid overresection that would have led to a “weak” appearance of the arm.

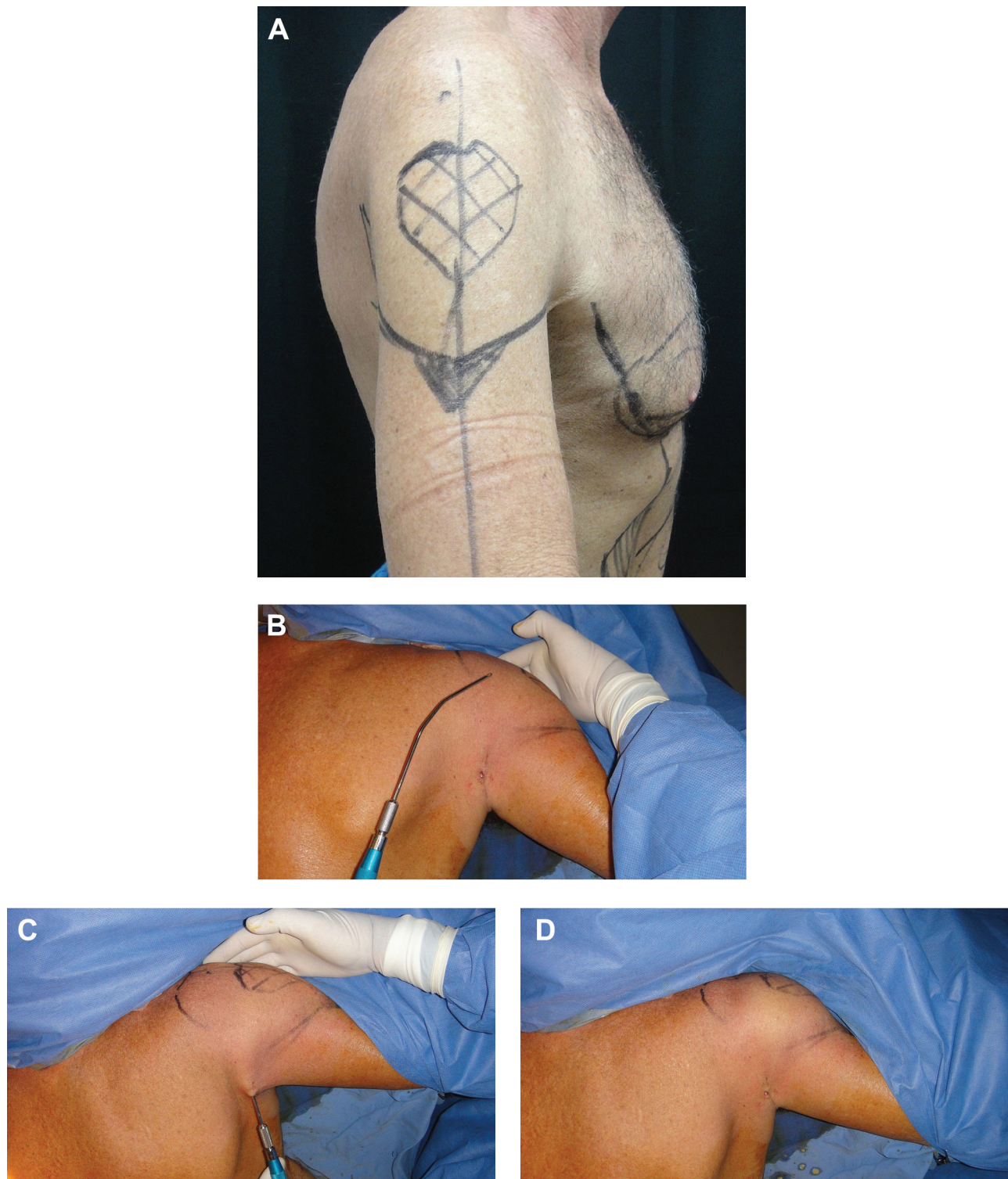

Figure 6. (A) A 54-year-old man is shown with preoperative markings for the area to receive fat grafting. (B) A 29-year-old man is shown in the prone position with a curved cannula for fat grafting. (C) A total of 50 mL of fat is injected into the patient shown in Part B, through the posterior axillary incision and following the curvature of the deltoid, while the depth and shape of the injection graft are controlled by the surgeon's free hand, and (D) the immediate postoperative result is shown.

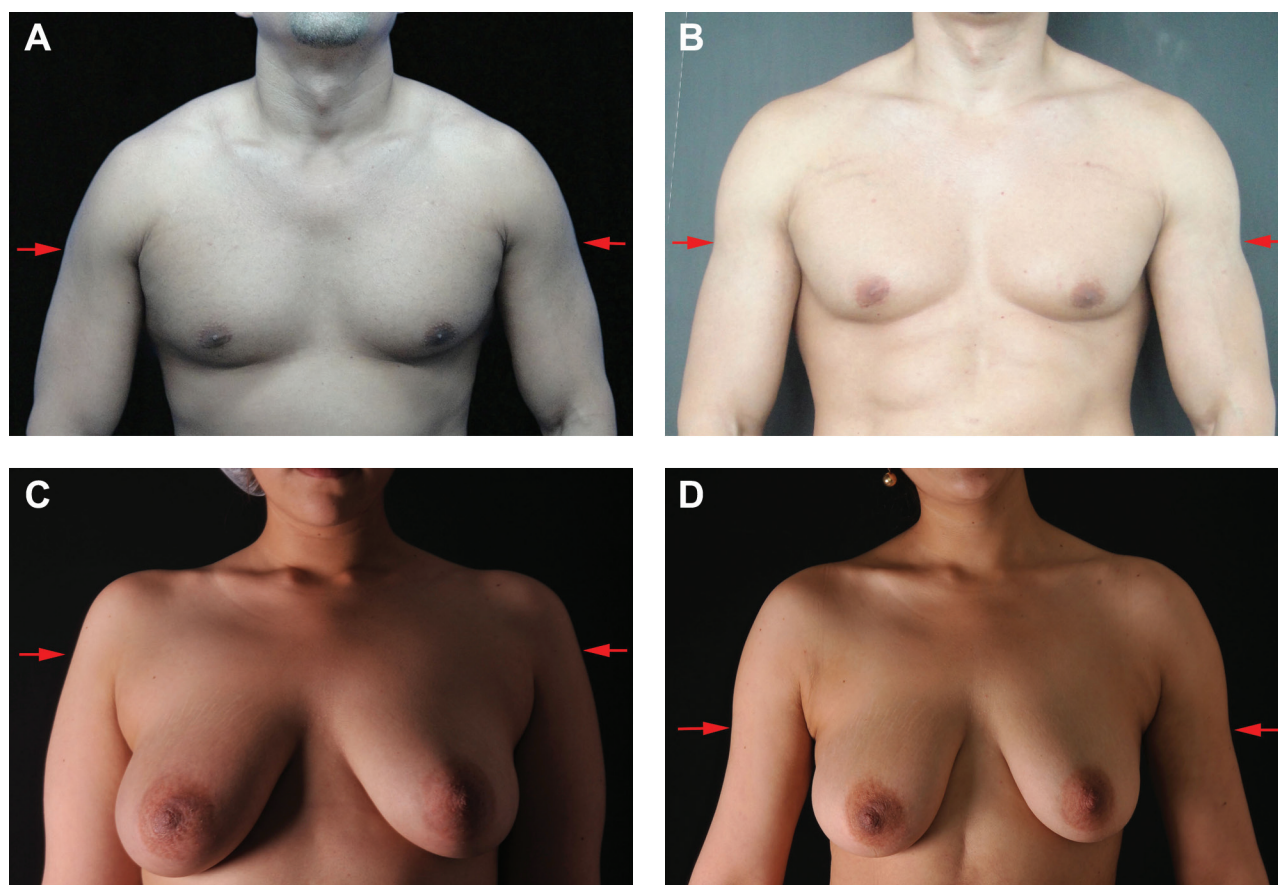


Figure 7. A 45-year-old man who required recreation of the deltoid sulcus is shown preoperatively (A) and 8 months after arm contouring with liposuction and fat grafting (B). In the preoperative image, the maximum width of the scapular belt is bitrochitic (arrows), whereas postoperatively, the maximum width is bideltoid (arrows). Note the more defined lateral curvature and the indentation of the triceps. A female patient (29 years old) who required similar deltoid sulcus recreation is shown preoperatively (C) and 6 months postoperatively (D). The slimmer curvature of the arm should be noted, along with the indentation of the deltoid in the anterior view (arrows), which is more slight than in male patients.

Via third-generation ultrasound (Sound Surgical Technologies, Denver, Colorado), emulsification was performed. The average time of emulsification was 2 minutes per 100 mL of tumescent solution infiltrated, but the clinical end point was the loss of tissue resistance. Emulsification was performed by starting in the superficial layer at 90% pulsed mode, using a 3.7-mm, 2-groove probe. In the deep layer, emulsification was applied in 90% continuous mode. Deep liposuction was performed with a 3-mm SST-6 VentX cannula (Sound Surgical Technologies) in the areas marked, mostly in the posterior arm.

Superficial liposuction was then performed to achieve skin retraction and contouring of the posterior proximal and distal arm. We used 45° and 30° angle, curved, 3-mm SST-6 VentX cannulae (Sound Surgical Technologies) to contour the deltoid sulcus (Figure 5). After the procedure

was complete, the incisions were sutured in the axillary ports with Prolene 4-0 (Ethicon, Inc, Somerville, New Jersey). The elbow wound was left open for drainage and covered with a sterile gauze pad.

Fat Grafting

Decantation was performed for the fat to be grafted. After the infranatant was extracted, clindamycin solution was added. Fat grafting was performed with a curved, 3-mm cannula (4D fat grafting cannula; Sound Surgical Technologies). Between 50 and 100 mL of fat was injected intramuscularly in the mid-fascicle of the deltoid to increase volume. This was done via the posterior axillary incision, by inserting the 3-mm curved cannula while the

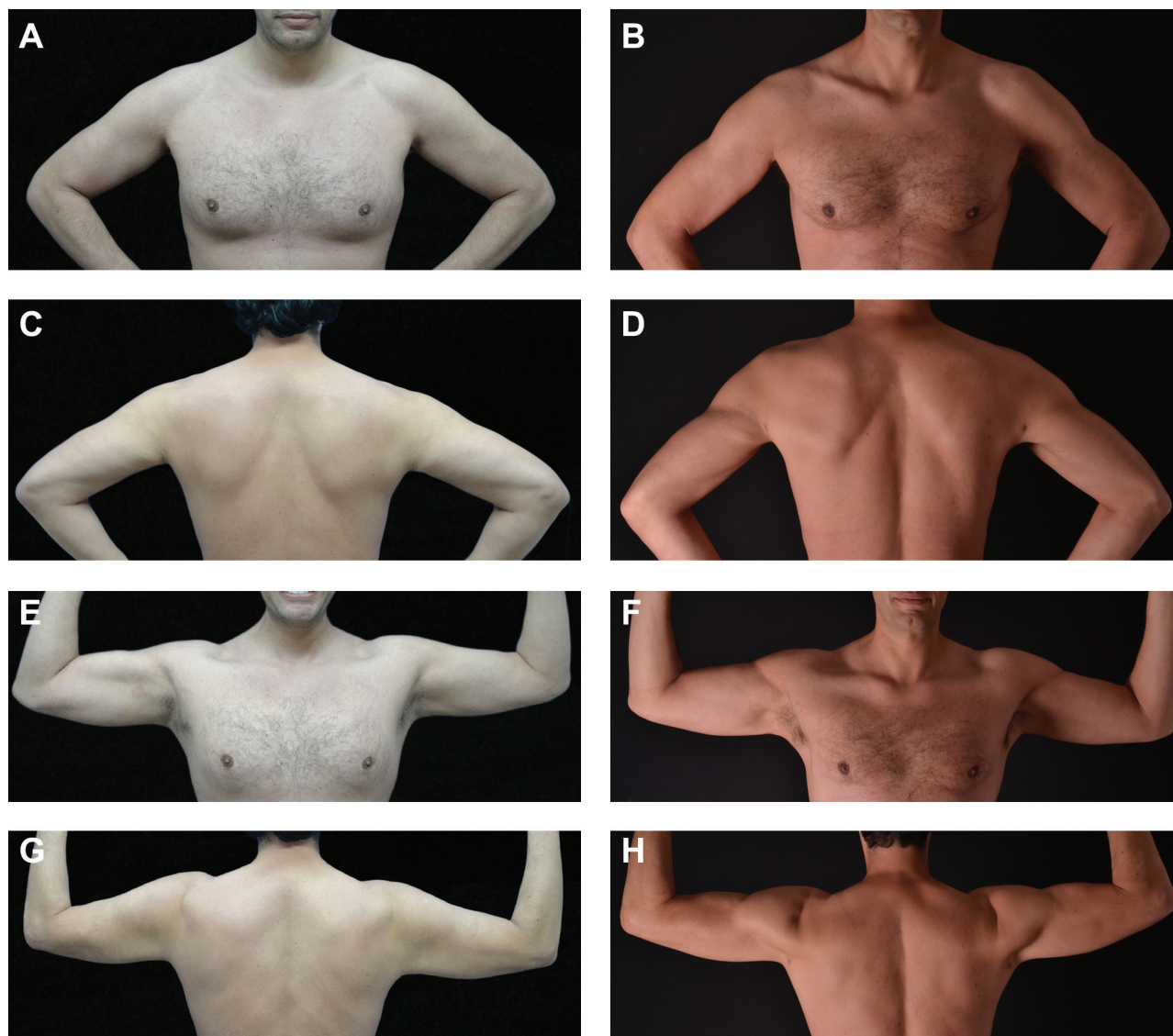


Figure 8. (A, C, E, G) This 38-year-old man presented after weight loss of approximately 66 pounds. (B, D, F, H) Seven months after arm contouring with the “dynamic definition” technique described by the authors, including 50 mL of fat grafting in each deltoid area. Note the deltoid definition and the muscular appearance in the postoperative images and the skin retraction, which was accomplished without skin excision.

surgeon’s free hand controlled the direction and depth of the cannula tip (Figures 6 and 7).

Postoperative Care

Postoperative care started after 24 to 48 hours. A compression garment was placed over the arm, extending beyond the elbow, for a period of 6 to 8 weeks. In all patients, an active postoperative treatment regimen was conducted, including an average of 10 sessions of lymphatic drainage massage accompanied by external ultrasound, as well as

infrared and local heating pads. The massage was intended to evacuate extra fluids through the elbow incision, which was left open for this purpose.

Full mobility of the arm was encouraged after 24 hours. Physical therapy was conducted in most patients to promote healing and improve the range of motion that could be restricted by transient skin hardening. The severity and duration of skin hardening was directly proportional to the subdermal release performed to obtain skin retraction. Stretching exercises were prescribed from 1 to 6 months postoperatively. Patients were evaluated at 24 to 48 hours, 1 week, and then 1, 3, and 6 months and 1 year after surgery.

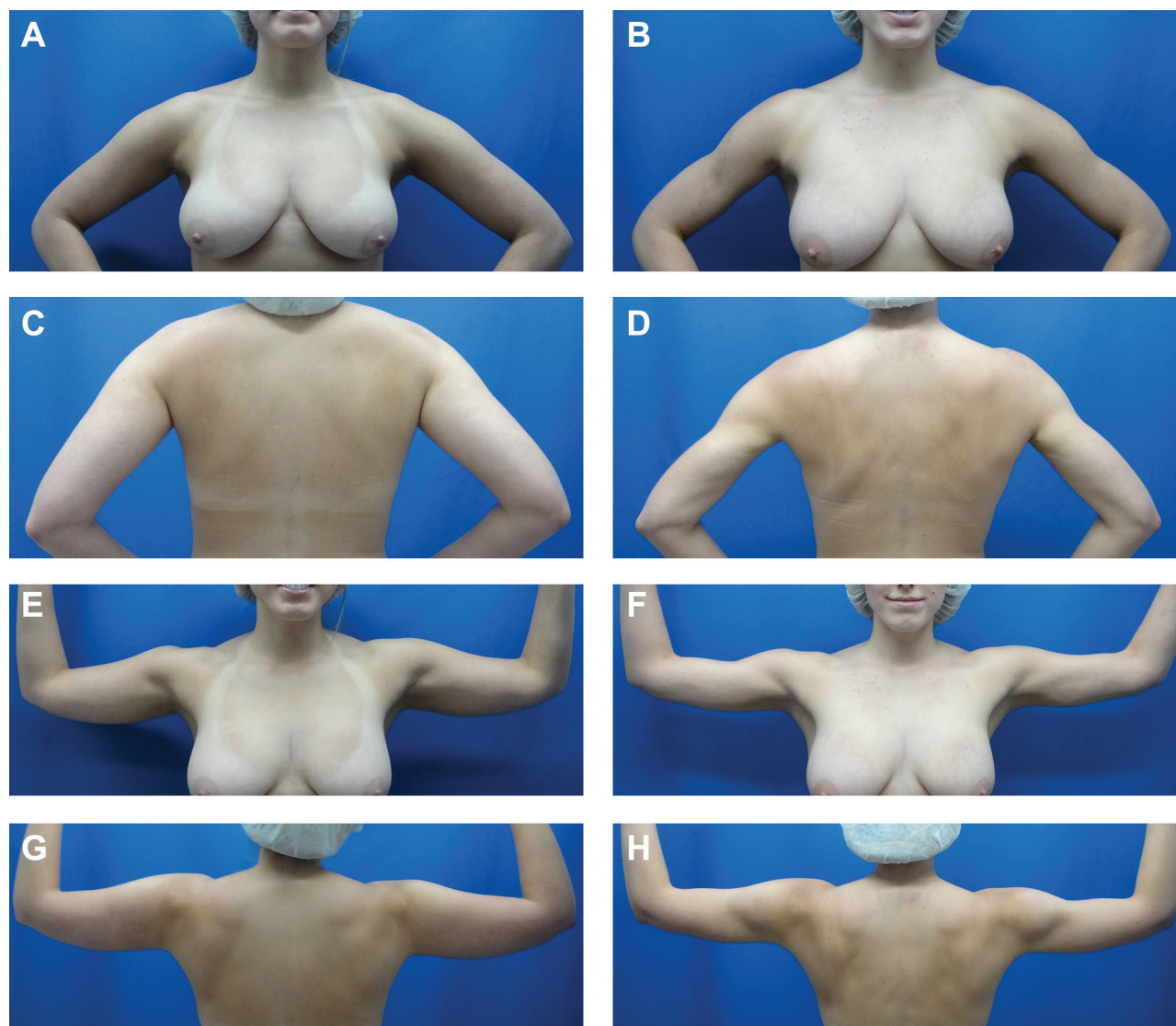


Figure 9. (A, C, E, G) This 29-year-old woman presented for arm contouring. (B, D, F, H) Six months after arm contouring with the “dynamic definition” technique described by the authors, including 300 mL of tissue removal from each arm. No fat grafting was performed. Note the slim and athletic result after the procedure, with corresponding skin retraction.

RESULTS

A total of 651 procedures were performed: 493 (75.7%) patients were women and 158 (24.3%) were men. Patient ages ranged between 15 and 56 years in women (average, 31.4 years) and 23 to 59 years in men (average, 36.7 years).

Patient satisfaction was assessed with a survey at the 6-month postoperative visit. Qualifications were as follows: 1 = bad results, 2 = below expectations, 3 = average, 4 = good results, and 5 = exceeded expectations. Of the 427 patients (65.6%) who completely answered the survey, the results were as follows: 378 (88.5%) patients

rated their results a 5, 42 (9.8%) rated their results a 4, 5 patients (1.2%) rated their results a 3, and only 2 patients (0.5%) felt that their results were a 2 (below expectations). If the 5 and 4 rankings are added, there was an overall satisfaction rate of 98.3% in our study population.

Only 21 local complications were reported (3.2%). No systemic complications were reported. There was 1 (0.15%) soft tissue abscess in the posterior arm zone that was treated by manual extraction and antibiotics (ampicillin/sulbactam 375 mg PO tid for 10 days). Two hematomas occurred (0.3%), and these were drained manually through the distal incision at the elbow pit without any secondary complications. Three seromas (0.46%) required

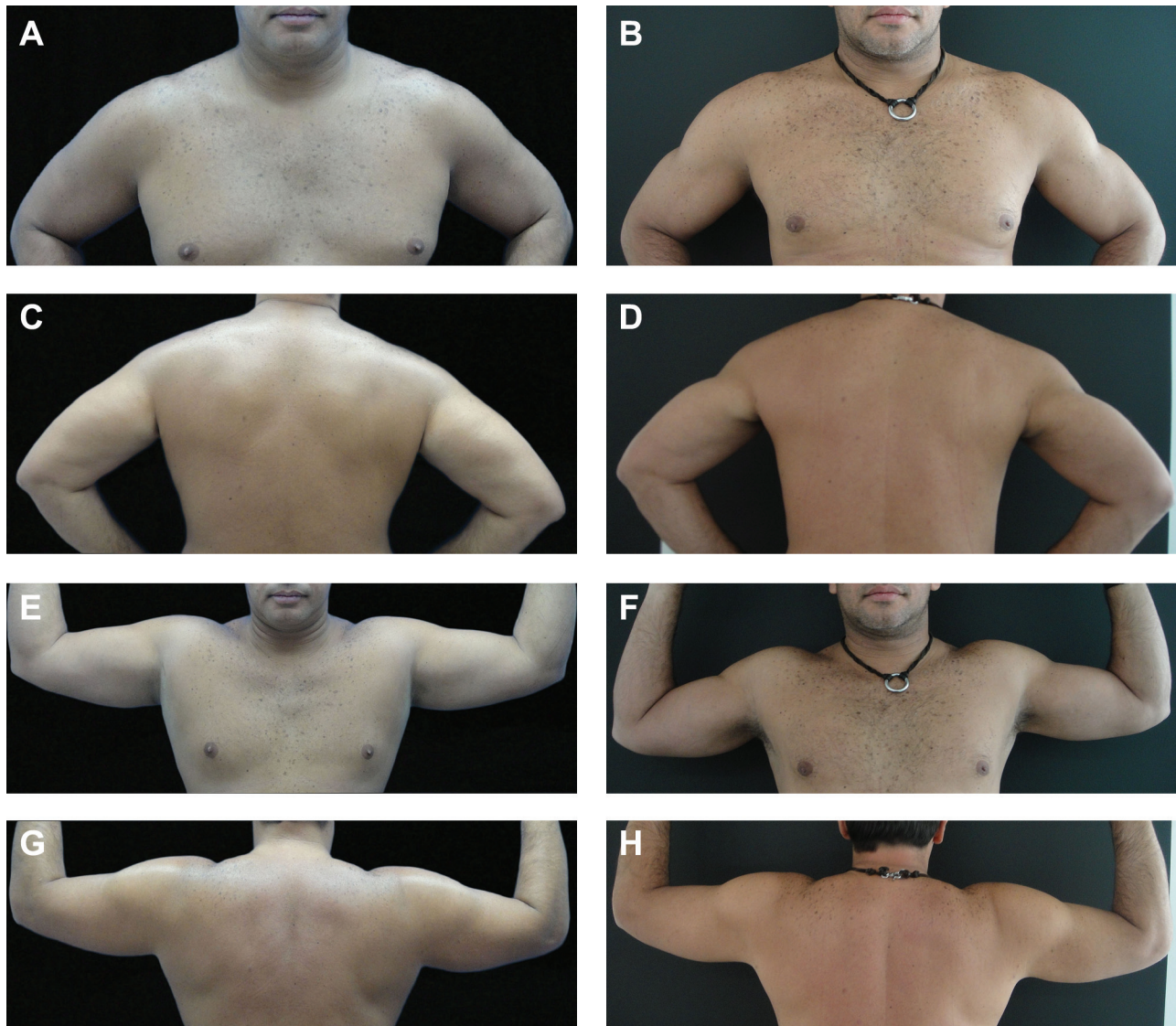


Figure 10. (A, C, E, G) This 45-year-old man presented for arm contouring. (B, D, F, H) Three months after arm contouring with the “dynamic definition” technique described by the authors, including 50 mL of fat grafting to each deltoid muscle. Notice that fat grafting improved the “well-built” appearance of the arm, while dynamic definition highlighted the muscles underneath.

puncture for extraction. Asymmetries were reported in 15 patients (2.3%). One hundred four patients (24.4%) complained about skin hardening a few days postoperatively, which can be explained by the superficial liposuction performed to obtain skin retraction and/or to superficially release the skin to correct immediate irregularities. After 6 months, all cases of hardening resolved.

Long-term follow-up continued for an average of 2.5 years (range, 2 months to 5 years). Pictures were taken in the postoperative period to assess the changes in arm contour and maintenance of the results over time.

Clinical results are shown in Figures 8 to 12.

Additional results are shown online in Appendices 1 to 8, which can be found at www.aestheticsurgeryjournal.com.

DISCUSSION

As we have established in previous publications,^{8,14} high-definition liposculpture is a safe and effective method of body contouring. In conjunction, fat grafting can be added to achieve better results in patients who require volumetric enhancement to correct deficiencies in specific areas of the

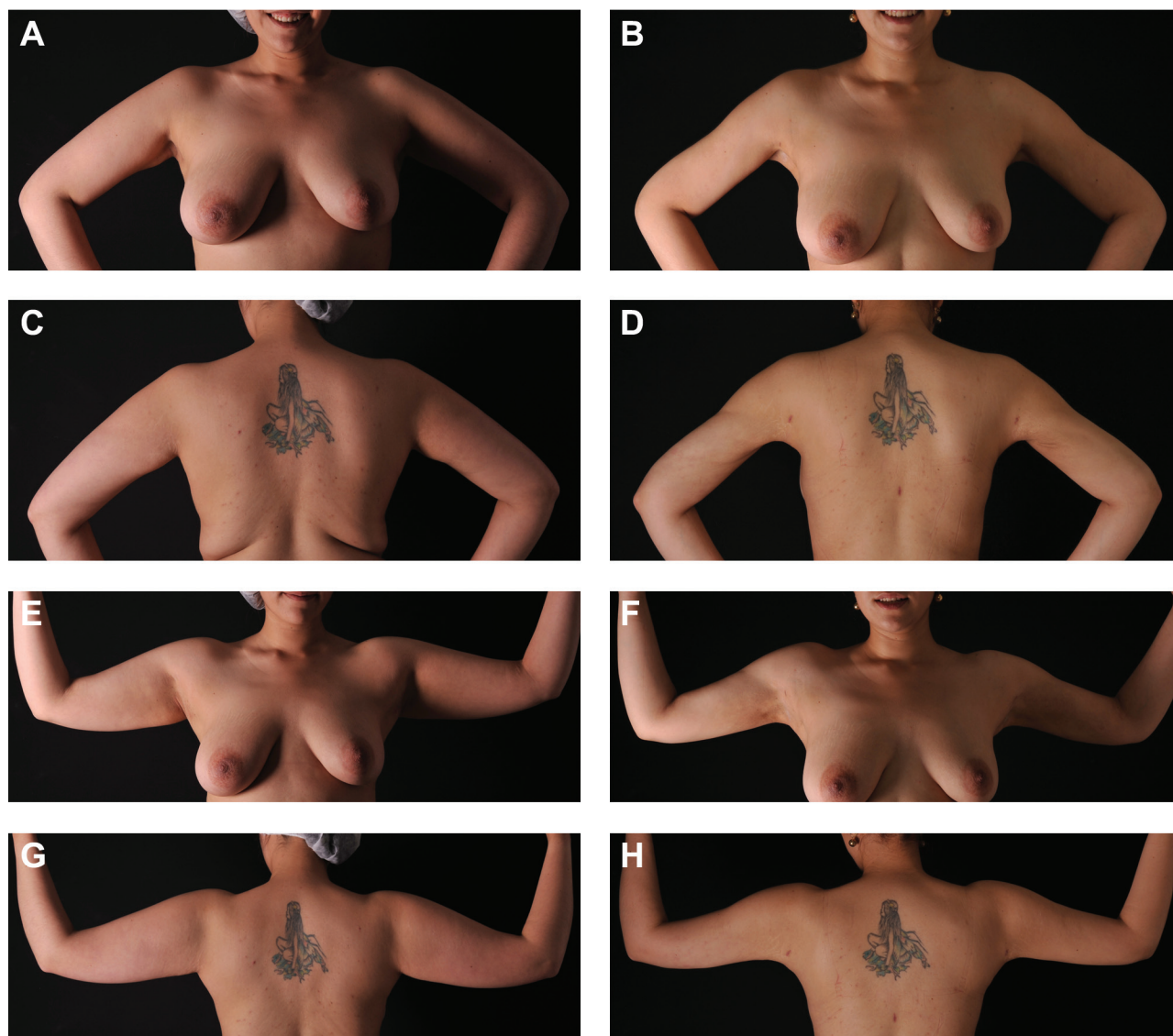


Figure 11. (A, C, E, G) This 24-year-old woman presented for arm contouring. (B, D, F, H) Six weeks after arm contouring with the “dynamic definition” technique described by the authors, including 360 mL of tissue removal from each arm. No fat grafting was performed. Note the patient’s improved aesthetic appearance.

arm. Although there is no consensus about follow-up in fat grafting,* some recent studies have reported that follow-up of 6 months is enough to observe the final “take” of fat retention in the muscles.^{43,69,71-73} We posit that further studies need to be undertaken to understand the behavior and survival of the fat in the deltoid area.

In our study, we enrolled a series of patients in whom this procedure achieved excellent results in most cases. Skin hardening in the posterior skin of the arm was a

temporary deformity that, beyond being a cause of concern to the surgeon and patient in the short term, we argue is actually a predictor of skin retraction over the long term. Skin retraction is predictable and desirable.

Many techniques have been reported in arm contouring for achieving better aesthetic and more natural results. A 360° approach to definition⁷ and radiofrequency-assisted liposuction^{4,5} have been previously described, but the literature lacked a description of a technique for achieving truly natural and slimmer results, which led us to develop a new technique to improve results. Multilayer and dynamic definition with fat grafting, as described in this case series, is a

*References 42, 43, 49, 57, 60, 62, 69-72.

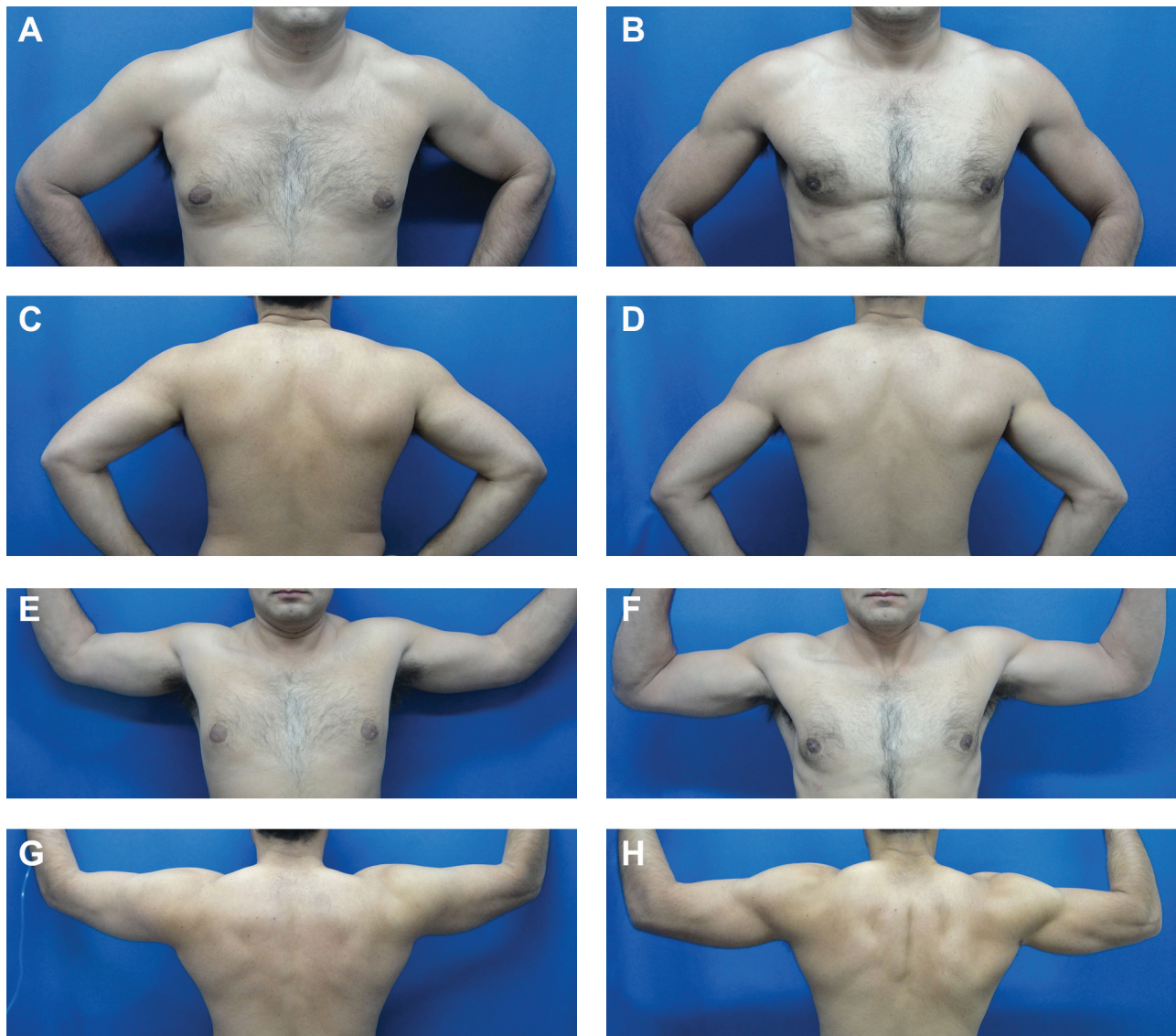


Figure 12. (A, C, E, G) This 42-year-old man presented for arm contouring. (B, D, F, H) Six months after arm contouring with the “dynamic definition” technique described by the authors, including 60 mL of fat grafting to each deltoid muscle. Note the athletic and muscular appearance to the arm, with curvature defined by the underlying muscle structure.

new option to accomplish the desired results in arm contouring for both men and women. The addition of patient arm motion into the preoperative marking process resolved the problems accompanying natural asymmetries and yielded natural results. Any new technique can be difficult to assimilate into clinical practice, but we believe that the learning curve for this technique can be shortened with adequate understanding of the arm anatomy at rest and in motion (dynamic concepts). Achieving the necessary expertise in this area will lead to excellent results with the technique described here. Dynamic definition can achieve athletic and natural results that can match the gender, age, body type, and wishes of the patient.

CONCLUSIONS

Ever since original liposuction techniques established an easy way of slimming and contouring various areas of the body, many procedures and modifications of the initial technique have been described. In this article, we were able to achieve natural results with a “dynamic definition” approach to liposculpting and fat grafting for arm contouring. The technique is safe and effective with reproducible results when performed through multilayer fragmentation and liposuction with an anatomical extraction. Most patients (more than 90%) reported satisfaction with their results, and the complication rate was small.

Disclosures

The authors declared no potential conflicts of interest with respect to the research, authorship, and/or publication of this article.

Funding

The authors received no financial support for the research, authorship, and publication of this article.

REFERENCES

- Appelt EA, Janis JE, Rohrich RJ. An algorithmic approach to upper arm contouring. *Plast Reconstr Surg*. 2006;118:237-246.
- Avelar J. Regional distribution and behavior of the subcutaneous tissue concerning selection and indication for liposuction. *Aesthetic Plast Surg*. 1989;13:155-165.
- Chamosa M, Murillo J, Vázquez T. Lipectomy of arms and lipograft of shoulders balance the upper body contour. *Aesthetic Plast Surg*. 2005;29(6):567-570.
- Duncan DI. Improving outcomes in upper arm liposuction: adding radiofrequency-assisted liposuction to induce skin contraction. *Aesthetic Surg J*. 2012;32(1):84-95.
- Gilliland MD, Lyos AT. CAST liposuction of the arm improves aesthetic results. *Aesthetic Plast Surg*. 1997;21(4):225-229.
- Glanz S, Gonzalez-Ulloa M. Aesthetic surgery of the arm: part I. *Aesthetic Plast Surg*. 1981;5:1-17.
- Hong YG, Sim HB, Lee MY, et al. Three-dimensional circumferential liposuction of the overweight or obese upper arm. *Aesthetic Plast Surg*. 2012;36(3):497-503.
- Hoyos AE. High definition liposculpture. Presented at: XIII International Course of Plastic Surgery; October 2003; Bucaramanga, Colombia.
- Lillis PJ. Liposuction of the arms. *Dermatol Clin*. 1999;17:783-797.
- Nguyen AT, Rohrich RJ. Liposuction-assisted posterior brachioplasty: technical refinements in upper arm contouring. *Plast Reconstr Surg*. 2010;126(4):1365-1369.
- Rohrich RJ, Beran SJ, Kenkel JM. *Ultrasound-Assisted Liposuction*. St Louis, MO: Quality Medical Publishing; 1998.
- Schlesinger SL. Suction-assisted lipectomy of the upper arm: a four-cannula technique. *Aesthetic Plast Surg*. 1990;14(4):271-274.
- Teimourian B, Malekzadeh S. Rejuvenation of the upper arm. *Plast Reconstr Surg*. 1998;102(2):545-551; discussion 552-553.
- Hoyos AE, Millard JA. VASER-assisted high definition lipoplasty. *Aesthetic Surg J*. 2007;27:594-604.
- Cimino WW, Bond LJ. Physics of ultrasound surgery using tissue fragmentation: part I. *Ultrasound Med Biol*. 1996;22:89-100.
- Cimino WW. The physics of soft tissue fragmentation using ultrasonic frequency vibrations of metal probes. *Clin Plast Surg*. 1999;26:447-461.
- Cimino WW. Ultrasound surgery: power quantification and efficiency optimization. *Aesthetic Surg J*. 2001;21:233-240.
- De Souza Pinto EB, Indaburo PE, Da Costa Muniz A, et al. Superficial liposuction: body contouring. *Clin Plast Surg*. 1996;23(4):529-548.
- De Souza Pinto EB. Morpho-histological analysis of abdominal skin as related to liposuction. *Aesthetic Plast Surg*. 1997;21(3):153-158.
- Fodor PB, Cimino WW, Watson JP, Tahernia A. Suction-assisted lipoplasty: physics, optimization, and clinical verification. *Aesthetic Surg J*. 2005;25:234-246.
- Gasparotti M, Lewis CM. *Superficial Liposculpture: Manual of Technique*. New York, NY: Springer-Verlag; 1990.
- Gasperoni C. Subdermal liposuction. *Aesthetic Plast Surg*. 1990;14:137-142.
- Gasparotti M. Superficial liposuction for flaccid skin patients. *Ann Int Symp Recent Adv Plast Surg*. 1990;90:441.
- Gasperoni C. Suction-assisted lipectomy of the subdermal liposuction fat layer: subdermal liposuction. *Ann Int Symp Recent Adv Plast Surg*. 1990;90:477.
- Gasparotti M. Superficial liposuction: a new application of the technique for aged and flaccid skin. *Aesthetic Plast Surg*. 1992;16:141-153.
- Gasperoni C. MALL liposuction: the natural evolution of subdermal superficial liposuction. *Aesthetic Plast Surg*. 1994;18:253-257.
- Gasperoni C. Rationale of subdermal superficial liposuction related to the anatomy of subcutaneous fat and the superficial fascial system. *Aesthetic Plast Surg*. 1995;19:13-20.
- Jewell ML, Fodor PB, de Souza Pinto EB, Al Shammari MA. Clinical application of VASER-assisted lipoplasty: a pilot clinical study. *Aesthetic Surg J*. 2002;22:131-146.
- Rohrich RJ, Beran SJ, Di Spaltro F, et al. Extending the role of liposuction in body contouring with ultrasound assisted liposuction. *Plast Reconstr Surg*. 1998;101:1090-1102.
- Scheflan M, Tazi H. Ultrasonically assisted body contouring. *Aesthetic Surg J*. 1996;16:117-122.
- Scuderi N, Paolini G, Grippaudo FR, Tenna S. Comparative evaluation of traditional, ultrasonic, and pneumatic assisted lipoplasty: analysis of local and systemic effects, efficacy, and costs of these methods. *Aesthetic Plast Surg*. 2000;24:395-400.
- Troilius C. Ultrasound-assisted lipoplasty: is it really safe? *Aesthetic Surg J*. 1999;23:307-311.
- Walgenbach KJ, Riabikhin AW, Galla TJ, et al. Effect of ultrasonic assisted lipectomy on breast tissue: histological findings. *Aesthetic Plast Surg*. 2001;25:85-88.
- Zocchi ML. Ultrasound-assisted lipoplasty. *Adv Plast Reconstr Surg*. 1995;11:197-221.
- Zocchi ML. Ultrasound-assisted lipoplasty: technical refinements and clinical evaluations. *Clin Plast Surg*. 1996;23:575-598.
- Zukowski ML. Ultrasound-assisted lipoplasty learning curve. *Aesthetic Surg J*. 1998;18:104-110.
- Cardenas-Camarena L, Lacouture AM, Tobar-Losada A. Combined gluteoplasty: liposuction and lipoinjection. *Plast Reconstr Surg*. 1999;104(5):1524-1531.

38. Carraway JH. Hand rejuvenation with structural fat grafting by Sydney R. Coleman. *Plast Reconstr Surg.* 2002;110(7):1745-1747.
39. Chajchir A. Comparative experimental study of autologous tissue processed by different techniques. *Aesthetic Plast Surg.* 1993;17:113-115.
40. Coleman SR. Facial recontouring with lipostructure. *Clin Plast Surg.* 1997;24:347-367.
41. Coleman SR. Hand rejuvenation with structural fat grafting. *Plast Reconstr Surg.* 2002;110(7):1731-1744.
42. Coleman SR. Structural fat grafting. *Plast Reconstr Surg.* 2005;115(6):1777-1778.
43. De Pedroza LV. Fat transplantation to the buttocks and legs for aesthetic enhancement or correction of deformities: long-term results of large volumes of fat transplant. *Dermatol Surg.* 2000;26(12):1145-1149.
44. Fournier P. Fat grafting: my technique. *Dermatol Surg.* 2000;26:1117-1128.
45. Guerrero-Santos J. Autologous fat grafting for body contouring. *Clin Plast Surg.* 1996;23(4):619-631.
46. Guisantes E, Fontdevila J, Rodríguez G. Autologous fat grafting for unaesthetic scars correction [published online May 27, 2011]. *Ann Plast Surg.*
47. Hudson DA, Lambert EV, Bloch CE. Site selection for fat autotransplantation: some observations. *Aesthetic Plast Surg.* 1990;14:195-197.
48. Lewis CM. Correction of deep gluteal depression by autologous fat grafting. *Aesthetic Plast Surg.* 1992;16:247-250.
49. Lewis CM. The current status of autologous fat grafting. *Aesthetic Plast Surg.* 1993;17:109-112.
50. Nordstrom RE, Wang J, Fan J. "Spaghetti" fat grafting: a new technique. *Plast Reconstr Surg.* 1997;99(3):917-918.
51. Pap GS. Autologous fat grafting for body contouring. *Plast Reconstr Surg.* 1998;101(4):1167-1168.
52. Pereira LH, Radwansky H. Fat grafting of the buttock and lower limbs. *Aesthetic Plast Surg.* 1996;20:409-416.
53. Toledo L, Mauad R. Fat injection: a 20-year revision. *Clin Plastic Surg.* 2006;33:47-53.
54. Yanai A. Lipoinjection. *Plast Reconstr Surg.* 2003;111(1):528.
55. Bircoll M. Cosmetic breast augmentation utilizing autologous fat and liposuction techniques. *Plast Reconstr Surg.* 1987;79(2):267-271.
56. De Blacam C, Momoh AO, Colakoglu S, Tobias AM, Lee BT. Evaluation of clinical outcomes and aesthetic results after autologous fat grafting for contour deformities of the reconstructed breast. *Plast Reconstr Surg.* 2011;128(5):411e-418e.
57. Illouz YG, Sterodimas A. Autologous fat transplantation to the breast: a personal technique with 25 years of experience. *Aesthetic Plast Surg.* 2009;33(5):706-715.
58. Mu DL, Luan J, Mu L, Xin MQ. Breast augmentation by autologous fat injection grafting: management and clinical analysis of complications. *Ann Plast Surg.* 2009;63(2):124-127.
59. Zheng DN, Li QF, Lei H, et al. Autologous fat grafting to the breast for cosmetic enhancement: experience in 66 patients with long-term follow up, *J Plast Reconstr Aesthetic Surg.* 2008;61(7):792-798.
60. Badran HA. Histopathologic changes of autogenous fat grafting in albino rats. *Plast Reconstr Surg.* 1997;99(2):607.
61. Carvajal J, Patiño JH. Mammographic findings after breast augmentation with autologous fat injection. *Aesthetic Surg J.* 2008;28(2):153-162.
62. Chajchir A. Fat injection: long-term follow-up. *Aesthetic Plast Surg.* 1996;20:291-296.
63. Chala LF, de Barros N, de Camargo Moraes P, et al. Fat necrosis of the breast: mammographic, sonographic, computed tomography, and magnetic resonance imaging findings. *Curr Probl Diagn Radiol.* 2004;33(3):106-126.
64. Fraser JK, Hedrick MH, Cohen SR. Oncologic risks of autologous fat grafting to the breast. *Aesthetic Surg J.* 2011;31(1):68-75.
65. Hyakusoku H, Ogawa R, Ono S, Ishii N, Hirakawa K. Complications after autologous fat injection to the breast. *Plast Reconstr Surg.* 2009;123(1):360-370; discussion 371-372.
66. Rubins DK. *The Human Figure: An Anatomy for Artists.* New York, NY: Penguin; 1976.
67. Schider F. *An Atlas of Anatomy for Artists.* New York, NY: Dover; 1957.
68. Simblet S, Davis J. *Anatomy for the Artist.* New York, NY: DK Publishing; 2001.
69. Carpaneda CA, Ribeiro MT. Percentage graft viability versus volume in adipose auto transplants. *Aesthetic Plast Surg.* 1994;18:17.
70. Ersek RA. Transplantation of purified autologous fat: a 3-year follow-up is disappointing. *Plast Reconstr Surg.* 1991;87:219-227.
71. Guerrero-Santos J. Long-term survival of free fat grafts in muscle: an experimental study in rats. *Aesthetic Plast Surg.* 1996;20:403-408.
72. Sommer B, Sattler G. Current concepts of graft survival: histology of aspirated adipose tissue and review of the literature. *Dermatol Surg.* 2000;26:1159-1166.
73. Baran CN, Celebioglu S, Sensoz O, Ulusoy G, Civelek B, Ortak T. The behavior of fat graft in recipient areas with enhanced vascularity. *Plast Reconstr Surg.* 2002;109:1646-1651.