

# Aesthetic Surgery Journal

<http://aes.sagepub.com/>

---

## Dynamic Definition Mini-Lipoabdominoplasty Combining Multilayer Liposculpture, Fat Grafting, and Muscular Plication

Alfredo E. Hoyos, Mauricio E. Perez and Luisana Castillo  
*Aesthetic Surgery Journal* 2013 33: 545  
DOI: 10.1177/1090820X13484493

The online version of this article can be found at:  
<http://aes.sagepub.com/content/33/4/545>

---

Published by:



<http://www.sagepublications.com>

On behalf of:



[American Society for Aesthetic Plastic Surgery](#)

**Additional services and information for *Aesthetic Surgery Journal* can be found at:**

**Email Alerts:** <http://aes.sagepub.com/cgi/alerts>

**Subscriptions:** <http://aes.sagepub.com/subscriptions>

**Reprints:** <http://www.sagepub.com/journalsReprints.nav>

**Permissions:** <http://www.sagepub.com/journalsPermissions.nav>

>> [Version of Record](#) - May 1, 2013

[What is This?](#)

# Dynamic Definition Mini-Lipoabdominoplasty Combining Multilayer Liposculpture, Fat Grafting, and Muscular Plication

Aesthetic Surgery Journal  
33(4) 545–560  
© 2013 The American Society for  
Aesthetic Plastic Surgery, Inc.  
Reprints and permission:  
[http://www.sagepub.com/  
journalsPermissions.nav](http://www.sagepub.com/journalsPermissions.nav)  
DOI: 10.1177/1090820X13484493  
[www.aestheticsurgeryjournal.com](http://www.aestheticsurgeryjournal.com)  


Alfredo E. Hoyos, MD; Mauricio E. Perez, MD; and  
Luisana Castillo, MD

## Abstract

**Background:** There is a select group of women for whom mini-abdominoplasty techniques combined with 3-dimensional liposculpture and fat grafting can effectively correct postpartum deformities.

**Objective:** The authors describe a multilayer and 360-degree approach, dynamic definition mini-abdominoplasty (DDM), to create athletic definition and contour and to restore a feminine appearance postpartum.

**Methods:** A total of 181 consecutive women ages 20 to 56 years underwent DDM between January 2005 and May 2012. Patients who were a minimum of 6 months postpartum and in good health, with a body mass index below 30, were considered for inclusion in the study. Fat grafting was performed in select cases in the buttocks, deltoids, and/or calves. A satisfaction index (SI) was estimated based on patient survey responses.

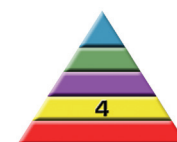**Results:** An overall SI of 91.5% was achieved. No major complications were reported. Twenty-nine minor complications included postoperative anemia, seroma, and infection in the surgical wound. In most patients, the postpartum abdomen was restored to an aesthetic and even athletic appearance. Athletic definition to the rectus, arms, trunk, thighs, and buttocks was also achieved. No burns or flap necrosis were reported.

**Conclusions:** Dynamic definition mini-abdominoplasty is safe and reproducible. It serves as a viable alternative to a full abdominoplasty in selected cases and for women who wish to restore an athletic and feminine appearance after childbirth.

## Level of Evidence: 4

## Keywords

liposuction, liposculpture, fat grafting, body contouring, lipoinjection, lipoabdominoplasty, tummy tuck, mini-abdominoplasty, postpartum



Accepted for publication October 30, 2012.

Abdominoplasty techniques have progressed notably since Demars and Marx first reported on them in 1890.<sup>1</sup> In 1899, the term *lipectomy* was coined by Kelly<sup>2</sup> in the United States, and descriptions of new liposuction techniques and other combined procedures followed. In 1992, Illouz<sup>3</sup> described liposuction-assisted abdominoplasty; lipoabdominoplasty was described by Avelar<sup>4,5</sup> in 1985 and 2006 and by Saldanha et al<sup>6</sup> in 2010. Abdominoplasty has become a very popular procedure and, in 2012, was the third most frequently performed cosmetic surgical procedure in the United States.<sup>4,5,7,8</sup>

Mini-abdominoplasty was introduced by Greminger<sup>9</sup> in 1987 and by Wilkinson<sup>10</sup> in 1988 after case report studies described women with skin laxity and excess in the lower

mid-region of the abdomen undergoing “limited” abdominoplasties with good and reproducible results. Many studies have attempted to develop new techniques to further improve mini-abdominoplasty.<sup>9–15</sup> One patient group that may benefit from such improvements is postpartum women.

Dr Hoyos is an Associate Professor in the Department of Plastic Surgery at the University of San Martin in Bogota, Colombia. Drs Perez and Castillo are plastic surgeons working in private practice in Bogota, Colombia.

## Corresponding Author:

Dr Alfredo E. Hoyos, Calle 99 #9A-80 Suite 1007, Bogota, Colombia.  
Email: [alhoyos@gmail.com](mailto:alhoyos@gmail.com)

Currently, indications for abdominoplasty in postpartum women are the presence of stretch marks and/or skin laxity.<sup>16-18</sup> In patients who do not have enough excess skin to receive a full abdominoplasty, a mini-abdominoplasty is more appropriate. Our procedure, in which a smaller scar is produced and the umbilicus is preserved,<sup>9-15</sup> is considered a refinement of the previous more invasive methods.

The combination of abdominoplasty and liposuction is also becoming more popular among plastic surgeons as it achieves aesthetic, reproducible, and harmonious results,<sup>3,5,6,13,19,20</sup> especially in postpartum women. Despite new advances, however, many of these procedures' original principles remain the same, and the quality of the results is sometimes far from optimal. An ideal procedure would define the rectus abdominis and oblique muscles, create an athletic contour, and take advantage of the skin retraction produced by superficial liposuction performed by third-generation ultrasound.<sup>21-41</sup> Here, we describe a new, minimally invasive procedure based on the principles of abdominoplasty (especially those described by Saldanha et al<sup>6</sup>) and high-definition multilayer liposculpture combined with selective fat grafting.<sup>42-44</sup> This procedure—with reproducible, aesthetically pleasing results—is called dynamic definition mini-abdominoplasty (DDM).

## METHODS

### Patients

A total of 181 postpartum women underwent DDM between January 2005 and May 2012 in 4 private or hospital-based surgical centers in Colombia. All procedures were performed by the senior author (A.E.H.), assisted by the other surgeons. To be eligible for the study, patients had to be a minimum of 6 months postchildbirth, be in general good health, and have a body mass index below 30. Patients with severe skin laxity were excluded. We do not recommend performing DDM on patients who are less than 6 months postpartum, as women are often still breastfeeding and have not yet regained normal uterine size and skin elasticity.<sup>16-18</sup>

### Procedural Criteria

Patients were evaluated preoperatively by an anesthesiologist and lab tests were performed according to American Heart Association guidelines. In patients with excess skin fat and laxity ( $n = 42$ , 23%), both aggressive deep liposuction and superficial liposuction were performed in the abdomen and surrounding areas to achieve skin retraction and to improve contour, whereas in patients with average skin fat and laxity ( $n = 139$ , 77%), mostly superficial liposuction was performed. In some cases, fat grafting restored aesthetic volume to the buttocks, deltoids, and/or calves; many other authors have published techniques for fat grafting in different body areas.<sup>45-55</sup> Body contouring was also performed in other areas: defining muscle groups in the abdomen, trunk, thighs, buttocks, and arms.

Cesarean section scars were used for access to the abdominal wall for plication of the rectus muscles in most patients ( $n = 152$ ) in both groups ( $n = 40$ , 95%;  $n = 112$ , 80%). Closed drains were left in the anterior abdominal area for 3 to 10 days and were removed only when drainage was less than 50 mL in 24 consecutive hours.

All patients received 2 g cefazolin, 8 mg dexamethasone, 8 mg ondansetron, 75 mg diclofenac, and 50 mg tramadol during the surgery. Oral ciprofloxacin was prescribed for 7 days postoperatively at 500 mg, twice per day. Patients who had more than 5000 mL of fat extracted remained overnight in the hospital. Pre- and postoperative photos were taken in anterior, lateral, posterior, and oblique positions. Postoperative photos were taken at 1 week and at 1, 3, 6, and 12 months, when possible.

## Surgical Technique

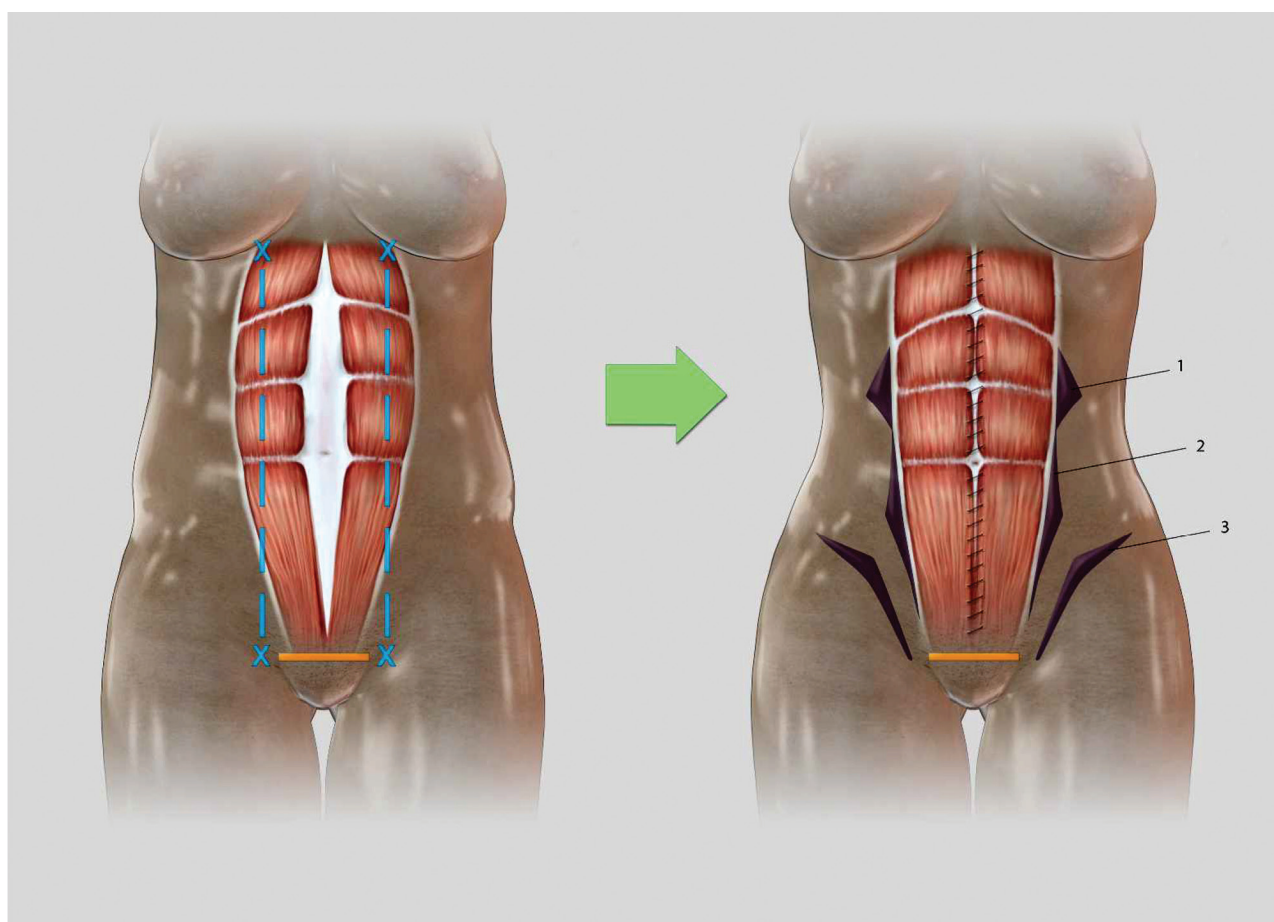
### Markings

For patients receiving deep liposuction, marks were made in the standing position to denote extra fat deposits in the trunk, abdomen, buttocks, thighs, and arms. The abdominal midline was also marked by palpation of the linea alba. The lateral border of the rectus was marked with dotted lines in the resting position, assuming that these were not in the original position compared with the prepregnancy state, which was to be restored by plication of the muscles. To predict where the rectus abdominis muscles were going to be located after the surgical procedure, the superior and inferior insertions of the rectus abdominis were marked in contraction, and a continuous line was drawn between these 2 points (we call them dynamic lines, due to the change of position of the lines after plication) (Figure 1). The same markings were made for all patients.

### Procedure

Five-millimeter incisions were made in the posterior axillary fold, elbow crease, infragluteal and intergluteal crease, inframammary fold, and suprapubic region medial to the lateral border of the rectus abdominis muscle. Silicone ports were fixed over the incisions with 4-0 silk sutures. Each area was infiltrated with standard tumescent solution (1000 mL normal saline, 10 mL 1% lidocaine, and 1 ampoule of epinephrine 1:1000) in the superficial and deep fat layers.<sup>56</sup> Fat emulsification was performed with third-generation ultrasound, blended between the superficial, intermediate, and deep fat layers with a 3.7-mm 2-ring probe (Sound Surgical Technologies, Denver, Colorado). In the superficial and intermediate layer, VASER liposuction (Sound Surgical Technologies) was used in 80% pulsed mode, and in the deep layer it was used in 80% continuous mode.

Deep liposuction was performed in the lateral and middle regions of the abdomen using 3.0- and 3.7-mm cannulae. The waistline area was suctioned with 4.6-mm and 3.0-mm curved and semi-curved Vent X cannulas (Sound Surgical Technologies). By utilizing a small-diameter and



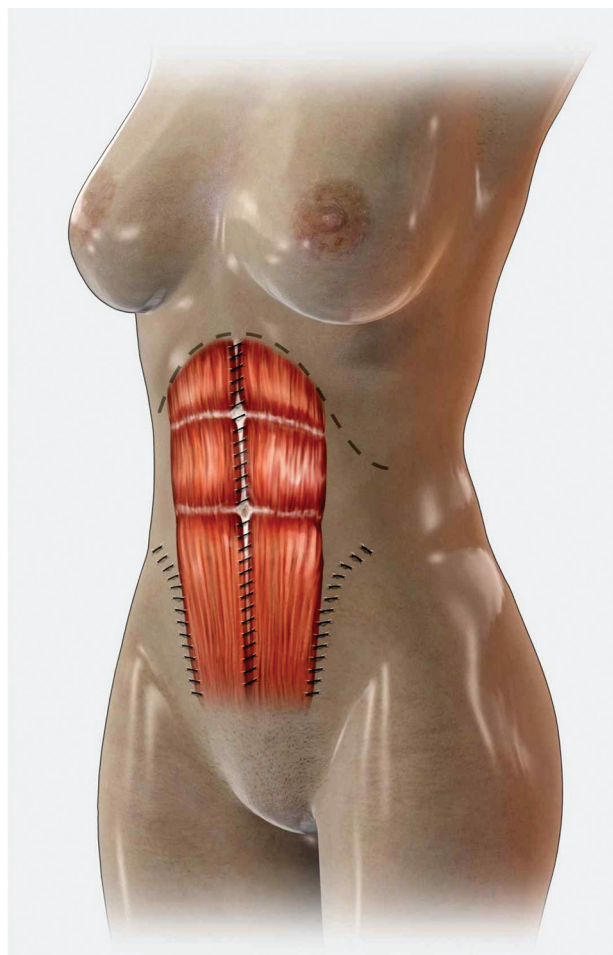
**Figure 1.** Markings for muscular plication. As the rectus abdominis muscle position is distorted, only the points of origin and insertion of the muscle are drawn, and these points are connected to predict the muscle position after plication (dynamic lines, in blue on the left). After restoration of the normal anatomy by muscular plication, the negative spaces (1, 2, and 3) fall in place of the semilunaris area.

low-trauma hole pattern, vascular injury over the flap was reduced. Superficial liposuction was performed with small cannulas (3.0 mm, 3.7 mm) for definition of the rectus (the predicted lines or dynamic lines), oblique abdominal muscles, and the linea alba, with the aim of preserving as many perforating vessels as possible for flap survival.

After liposuction, a transverse incision was made over the suprapubic region in the same position as in the Pfannestiel technique described for cesarean surgery.<sup>57</sup> The fold over the pubis marked the horizontal section of the skin in the superior border of the pubic hair, following a convex curved line from 10 to 12 cm long. The anterior abdominal flap was raised from the pubic incision to the xiphoid process, releasing the umbilicus from its base to access the upper abdominal flap. Hemostasis was carefully performed in the flap, and the rectus abdominis muscle was plicated by 2-layer stitching consisting of double-x buried stitches with 0 Nurodon (Ethicon, Inc, Somerville, New Jersey) sutures and running 0 Vicryl sutures. Plication was performed so as to

avoid overcorrection of the rectus abdominis muscle, which can result in nonanatomical definition and the appearance of a “double” rectus abdominis. When more plication was needed, oblique muscle plication was performed bilaterally in the lower abdomen (Figure 2). The flap and the umbilicus were then fixed to the muscular fascia with 4-0 Vicryl running sutures. In the upper abdomen, larger bites were taken with the running sutures, so that they reached under the dermis of the flap to increase midline supraumbilical definition. In the lower abdomen, the stitches were placed only in the deep fat of the flap (Figure 3). Silicone negative-pressure drainage was applied between the flap and the fascia. Closure was performed from deep to superficial layers, skin and fat excess were removed, and the wound was sutured. Deep-layer aspiration was repeated for further debulking. Superficial-layer aspiration completed the procedure and defined “athletic” depressions such as the linea alba, the lateral borders of the rectus, and the oblique muscles.





**Figure 2.** Muscular plication is performed in a manner that does not overcorrect the rectus abdominis muscle. If more plication is needed, oblique muscle plication is performed bilaterally in the lower abdomen.

### Fat Grafting

Fat harvesting was performed with a 3-mm blunt cannula, and 1 g cefazolin was added to an empty, sterile bottle trap. Decantation separated the fat cells from the saline and serosanguineous components. A high-density supernatant was used for multilayer fat grafting, which was performed with a 3-mm blunt cannula to restore aesthetically pleasant anatomy and even distribution in hips, buttocks, deltoids, and calves in selected cases.

### Satisfaction Ratings

We estimated a patient satisfaction index (SI) by distributing an unvalidated survey to patients at their control visit, at 6 and 12 months postoperatively. They were asked to grade the results of their procedure as “poor,” “below expectations,” “average,” “good,” or “above expectations.” Patients and surgeons also looked at pre- and postoperative

photographs to evaluate results, although no formal surgeon SI was performed.

## RESULTS

Average patient age was 35.3 years (range, 20-56 years). In most patients, the postpartum abdomen was restored to an aesthetic and symmetrical appearance. Athletic definition to the rectus, arms, trunk, thighs, and buttocks was also achieved. Fat tissue extraction volume ranged from 2000 to 8600 mL (average, 3460 mL) and fat grafting volume varied from 0 to 900 mL (average, 534 mL). One hundred thirty-six (75%) patients received lipoinjections in their buttocks, hips, and calves.

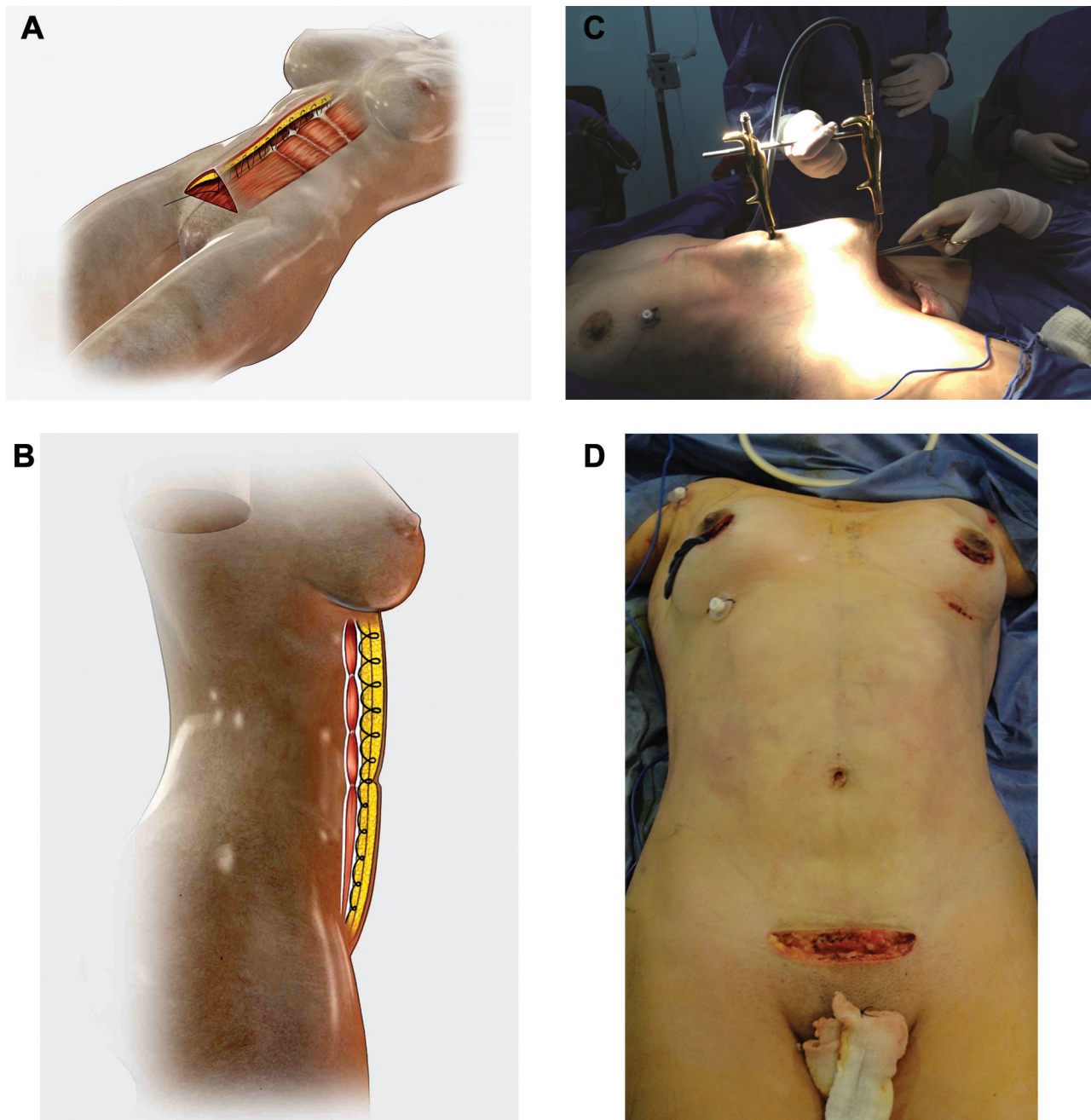
One hundred forty-one patients (78%) completed the postoperative survey, and the scores reported were as follows: above expectations, 103 patients (73.1%); good, 26 patients (18.4%); average, 8 patients (5.7%); below expectations, 3 patients (2.1%); and poor, 1 patient (0.7%). The patient who reported poor results complained of issues associated with scar retraction. By adding the percentages of patients who reported good and above expectations results, we obtained a final SI of 91.5%.

No major postoperative complications were reported. Twenty-nine minor complications (16%) were reported, including postoperative anemia in 5 patients (2.7%), all of whom required transfusion of 1 red blood cell unit each. This complication occurred in patients with bulky flap resection and large liposuction volume extraction. Seromas were reported in 20 patients (11%); all of these were associated with premature drain removal (prior to achieving less than 50 mL of drainage in 24 consecutive hours). This also caused abnormal skin retraction in 2 of these 20 patients (1.1%); these were spontaneously resolved within 6 months (Figure 4). Four superficial local infections (2.2%) were reported, all of which were resolved with antibiotic therapy (400 mg moxifloxacin by mouth once per day and 250 mg clarithromycin by mouth twice per day for 10 days). No cases of skin burns or skin flap necrosis were reported.

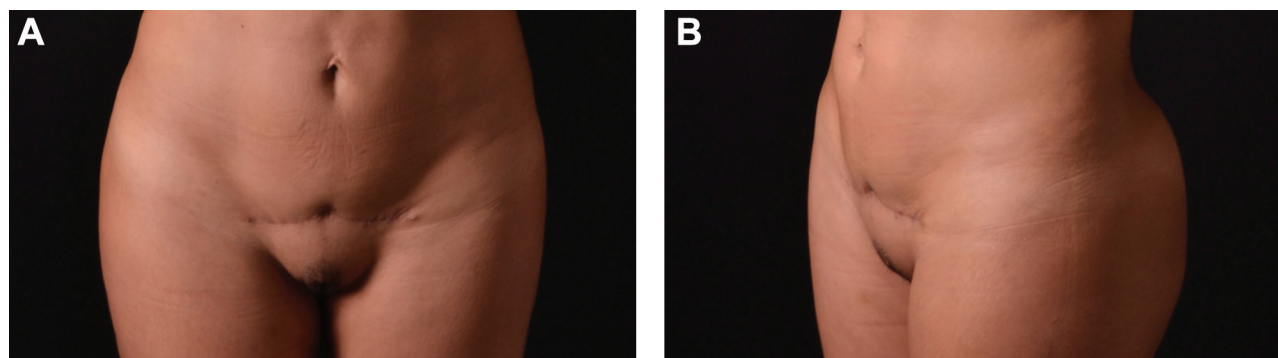
Clinical results are shown in Figures 5 through 7. (Additional results are shown in Figures 9 through 14, which are available online at [www.aestheticsurgeryjournal.com](http://www.aestheticsurgeryjournal.com).)

## DISCUSSION

Following childbirth, most women complain of remaining skin in the central region of their abdomen. Stretch marks and laxity are also frequent concerns. Liposuction may be the best treatment for thinner women with minor skin excesses and fat deposits, while full abdominoplasty may be best for obese women with severe skin laxity, umbilical ptosis, and abundant abdominal fat deposits. However, these procedures might not be the best aesthetic solution for some women, including those desiring minimally invasive procedures as well as minimal postoperative scarring; we consider these specific indications for DDM.



**Figure 3.** (A, B) A running suture connects the flap and the umbilicus to the muscular fascia. In the flap, from the xiphoid to the umbilicus, larger bites are taken, encompassing both superficial and deep fat (including the Scarpa's fascia) to produce midline definition. Below the umbilicus, the stitches grasp the deep fat only. (C, D) The flap-closing process is shown intraoperatively in a 29-year-old woman who underwent dynamic definition mini-abdominoplasty. Note the manner of access toward the xyphoid using the interlocking retractor (Marina Medical, Miami, Florida) (C) and the immediate postoperative appearance (D).



**Figure 4.** (A, B) This 32-year-old woman demonstrates severe scar retraction after dynamic definition mini-abdominoplasty at the 6-month control visit.

The preoperative location of the umbilicus is slightly more controversial as an indication for mini versus full abdominoplasty. Different reports have attempted to homogenize its placement, but it is difficult to standardize.<sup>12,58-60</sup> We believe that placing the umbilicus in an area that is aesthetically pleasant begins by drawing a point in the middle of the line between the xiphoid process and the pubic symphysis. We then make a second point at the intersection between the upper two-thirds and lower one-third of that same line. We consider the zone limited by these 2 points optimal for umbilicus placement. In our opinion, when a patient has a high umbilicus and low supraumbilical skin redundancy preoperatively, she is the perfect candidate for DDM. If the preoperative umbilicus is in or below the second point described above, she would be a better candidate for a full abdominoplasty (Figure 8).

Since Greminger<sup>9</sup> and Wilkinson<sup>10</sup> described mini-abdominoplasty, many techniques that aim to restore a natural and slim figure in postpartum women have been published. Some of these techniques do not seem aesthetically optimal, as the resulting visible scars do not satisfy patient expectations. It does seem that W-shaped, “smile-like,” and new novel transposition<sup>12</sup> scars are slightly more aesthetically pleasing than those resulting from full abdominoplasty, but they are still too large for some patients’ liking. It is our belief that DDM is an improved method, as complaints pertaining to scarring from patients in our study were minimal.

Overall satisfaction indices reported in various other studies attempting similar techniques were quite poor,<sup>10,11,13-15</sup> but we achieved a very high SI based on the patients’ subjective opinions of their procedural results. It is not the purpose of this report to standardize a surgical technique with statistical support but to provide a new approach for body contouring with improved results.

Our patients’ satisfaction can be partially attributed to the smaller incision made for flap resection, which was made possible by ultrasound-assisted liposculpture and associated reduction of flap length. Although many authors

have documented their approaches for abdominal contouring, including liposuction-assisted techniques, neither ultrasound-assisted nor 3-dimensional liposculpture has been described for mini-abdominoplasty. Therefore, our technique, which focuses on a 360-degree approach to body contouring as well as dynamic body definition with ultrasound-assisted liposuction, is an improvement to classic mini-abdominoplasty.

Despite the different lipoinjection techniques that have been described in diverse body areas for muscular enhancement, dermal fillers, and contour deformities, recent studies have made it a controversial procedure,<sup>61-67</sup> and long-term results have been questioned. Fat grafting allowed us to achieve slimmer curves and volumize gain-desired areas for certain patients. Our purpose is not to deem fat grafting the only option for volume enhancement but to establish it—by way of our results in this study—as an option for positive and long-term results. We believe fat grafting/lipoinjection is a very good alternative for women who desire better curve definition and correction of fatty or muscular tissue that is aesthetically unpleasant.<sup>68-71</sup>

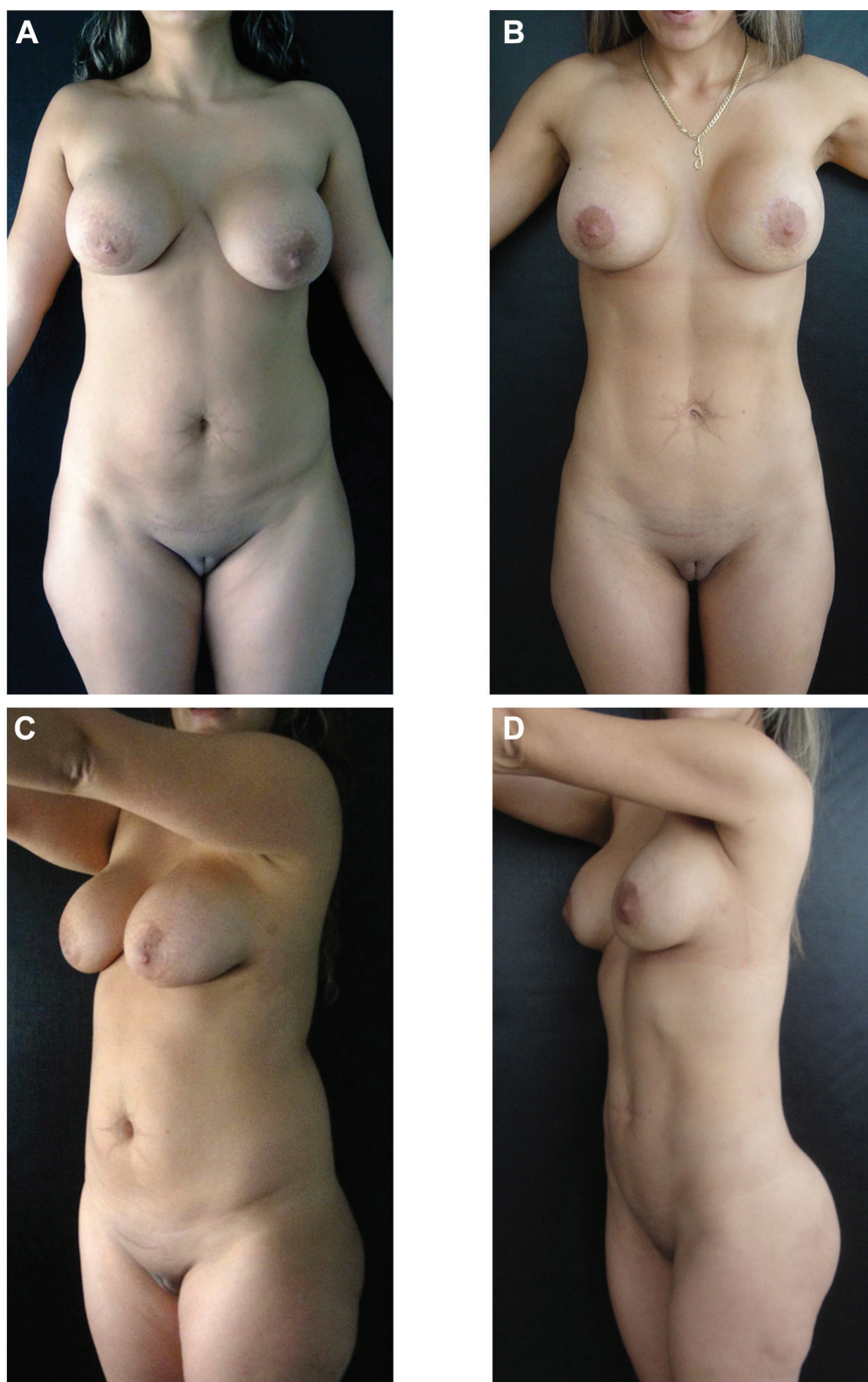
## CONCLUSIONS

Dynamic definition mini-abdominoplasty is a safe and reproducible approach for select women who wish to regain feminine body features after childbirth. It produces better aesthetic results than traditional full abdominoplasty due to minimized scarring and due to muscular plication and fat grafting, which provide definition of the body contour and enhancement of the zones responsible for making women look slimmer and more feminine.

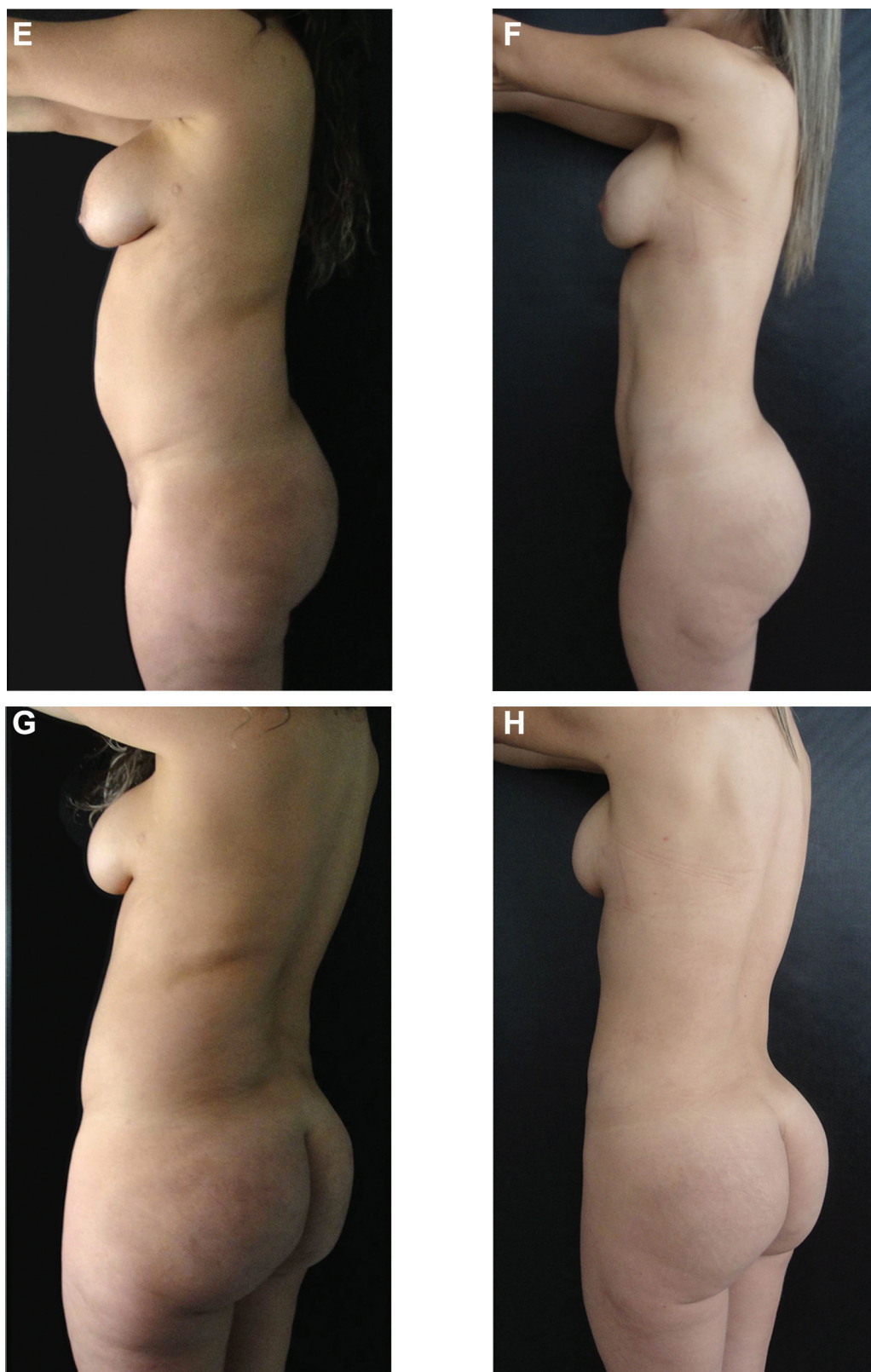
## Disclosures

The authors declared no potential conflicts of interest with respect to the research, authorship, and publication of this article.



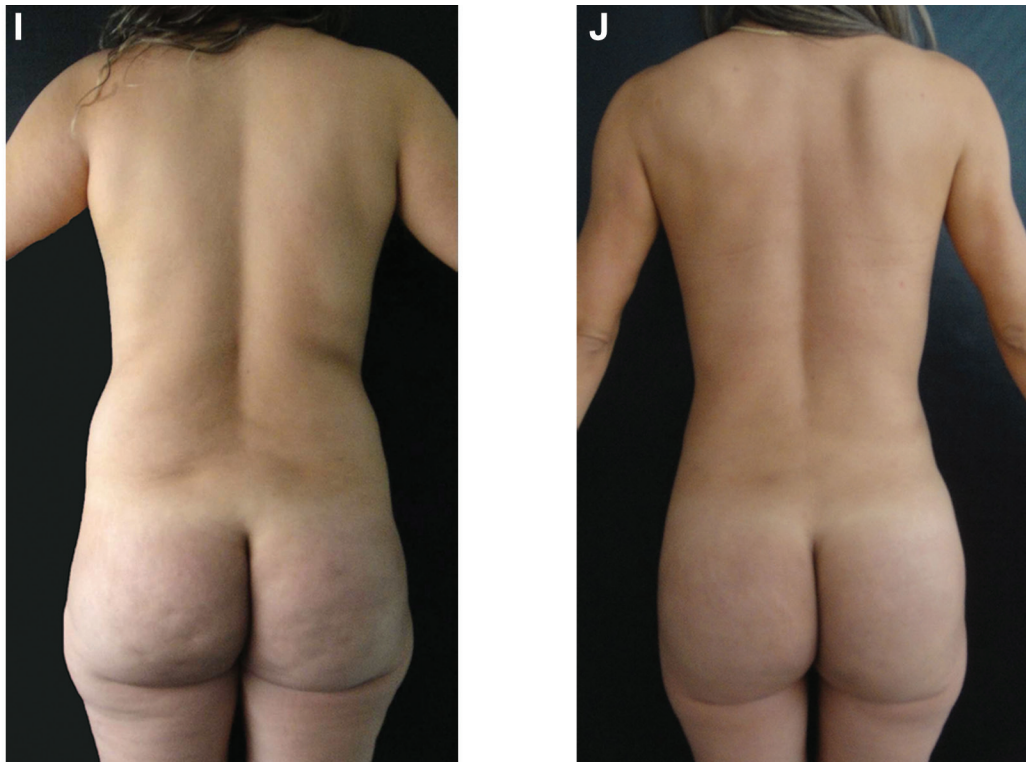


**Figure 5.** (A, C, E, G, I) This 32-year-old woman presented for dynamic definition mini-abdominoplasty. Note the protrusion of her anterior abdomen in the central area, indicating rectus abdominis muscle diastasis. (B, D, F, H, J) Eight months after liposuction, with extraction of 5500 mL in the patient's arms, back, abdomen, hips, and waist. Fat grafting was also performed in the buttocks (350 mL on each side). Note the change in definition of the anterior abdominal contour; waistline reduction was due both to muscle plication and liposuction. Periareolar mastopexy was also performed on this patient.

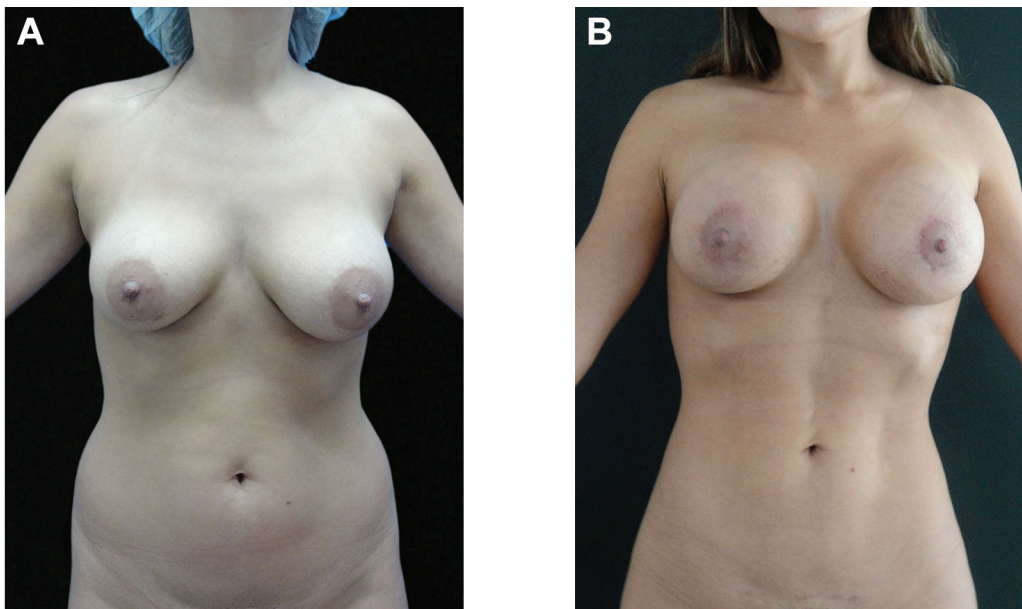


**Figure 5. (continued)** (A, C, E, G, I) This 32-year-old woman presented for dynamic definition mini-abdominoplasty. Note the protrusion of her anterior abdomen in the central area, indicating rectus abdominis muscle diastasis. (B, D, F, H, J) Eight months after liposuction, with extraction of 5500 mL in the patient's arms, back, abdomen, hips, and waist. Fat grafting was also performed in the buttocks (350 mL on each side). Note the change in definition of the anterior abdominal contour; waistline reduction was due both to muscle plication and liposuction. Periareolar mastopexy was also performed on this patient.

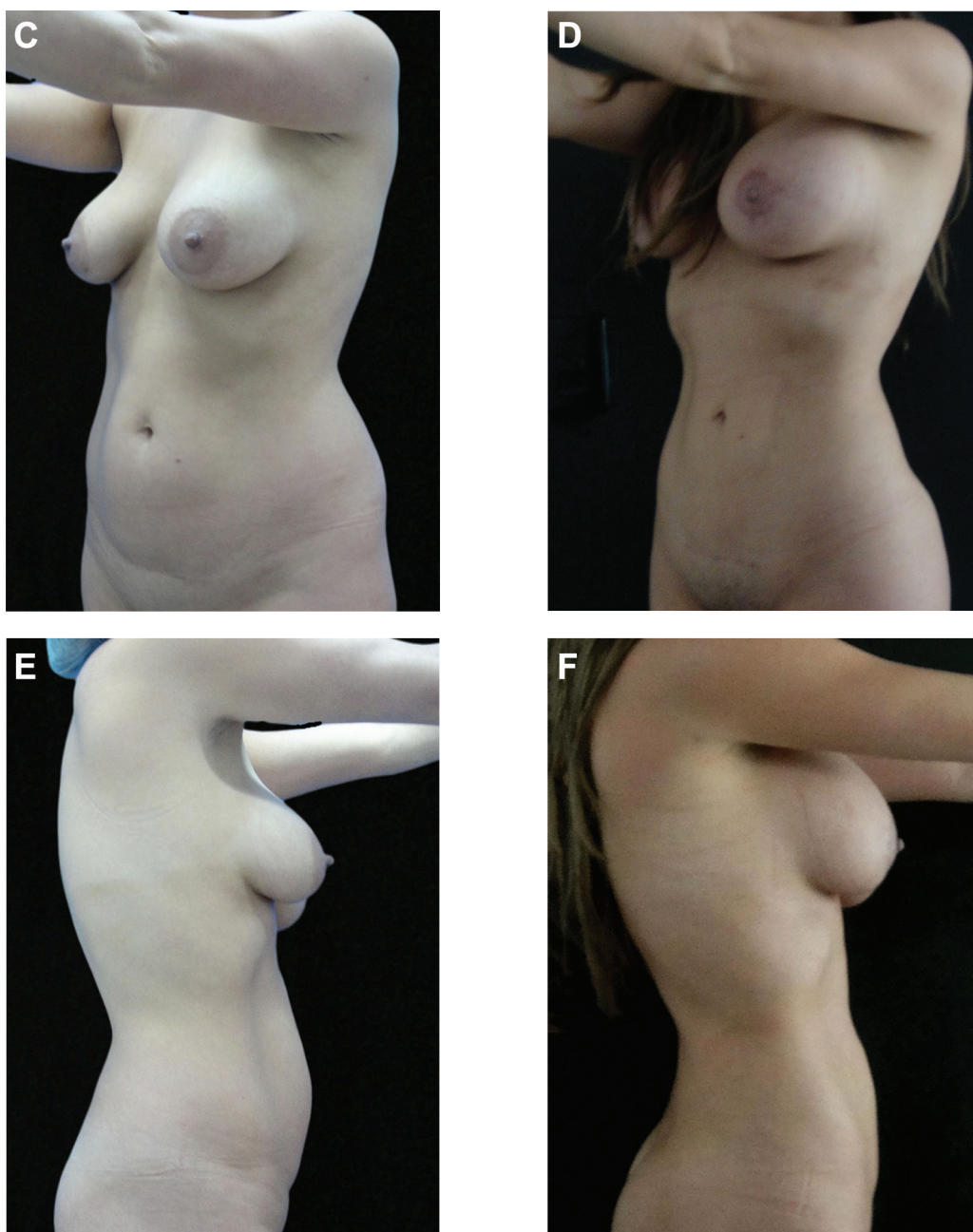




**Figure 5. (continued)** (A, C, E, G, I) This 32-year-old woman presented for dynamic definition mini-abdominoplasty. Note the protrusion of her anterior abdomen in the central area, indicating rectus abdominis muscle diastasis. (B, D, F, H, J) Eight months after liposuction, with extraction of 5500 mL in the patient's arms, back, abdomen, hips, and waist. Fat grafting was also performed in the buttocks (350 mL on each side). Note the change in definition of the anterior abdominal contour; waistline reduction was due both to muscle plication and liposuction. Periareolar mastopexy was also performed on this patient.

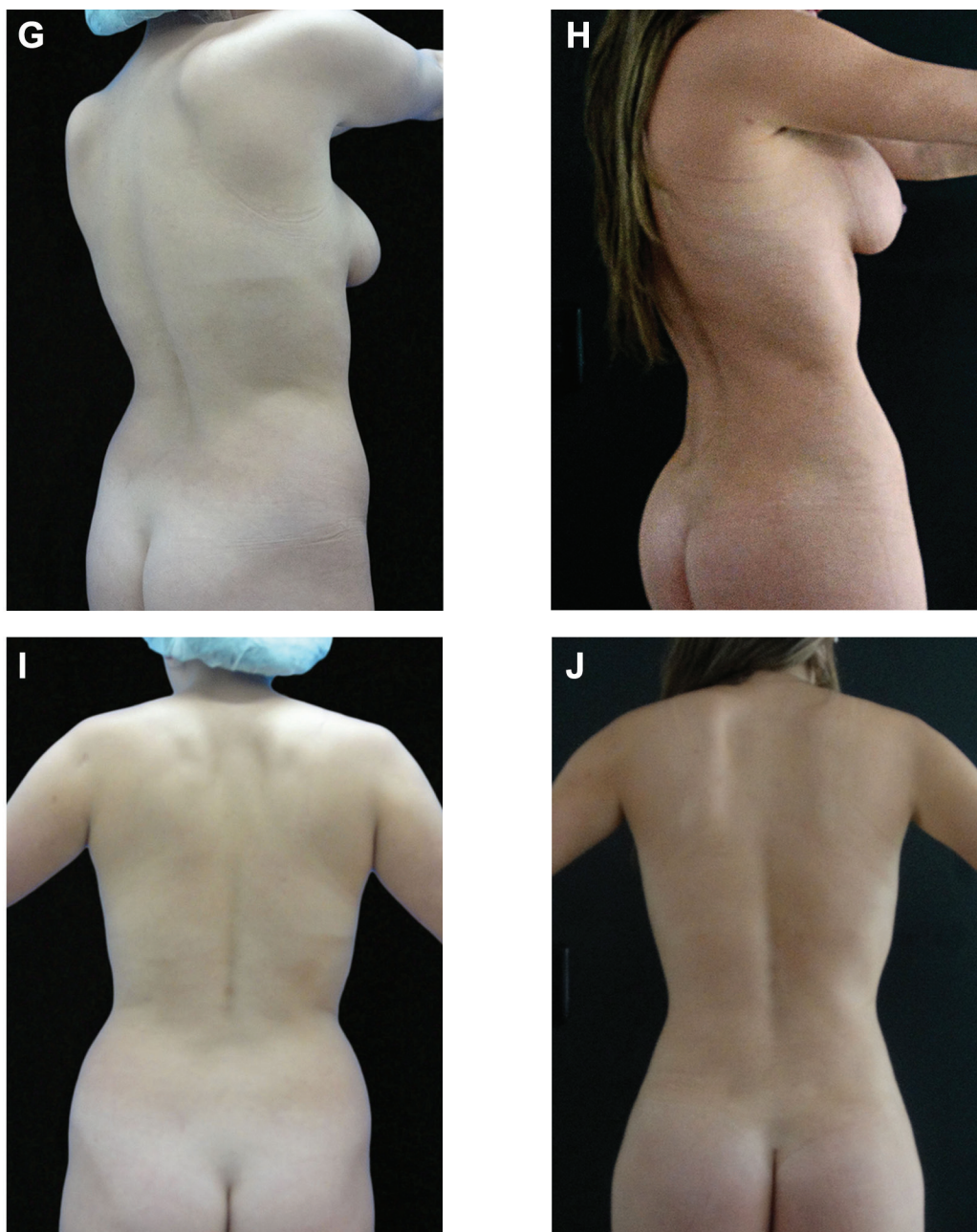


**Figure 6.** (A, C, E, G, I) This 30-year-old patient presented for dynamic definition mini-abdominoplasty. (B, D, F, H, J) One year after liposuction extraction of approximately 4000 mL in her arms, back, abdomen, hips, and waist. Fat grafting was performed in the buttocks (200 mL on each side). Note the overall change in the contour and the enhanced athletic shape.

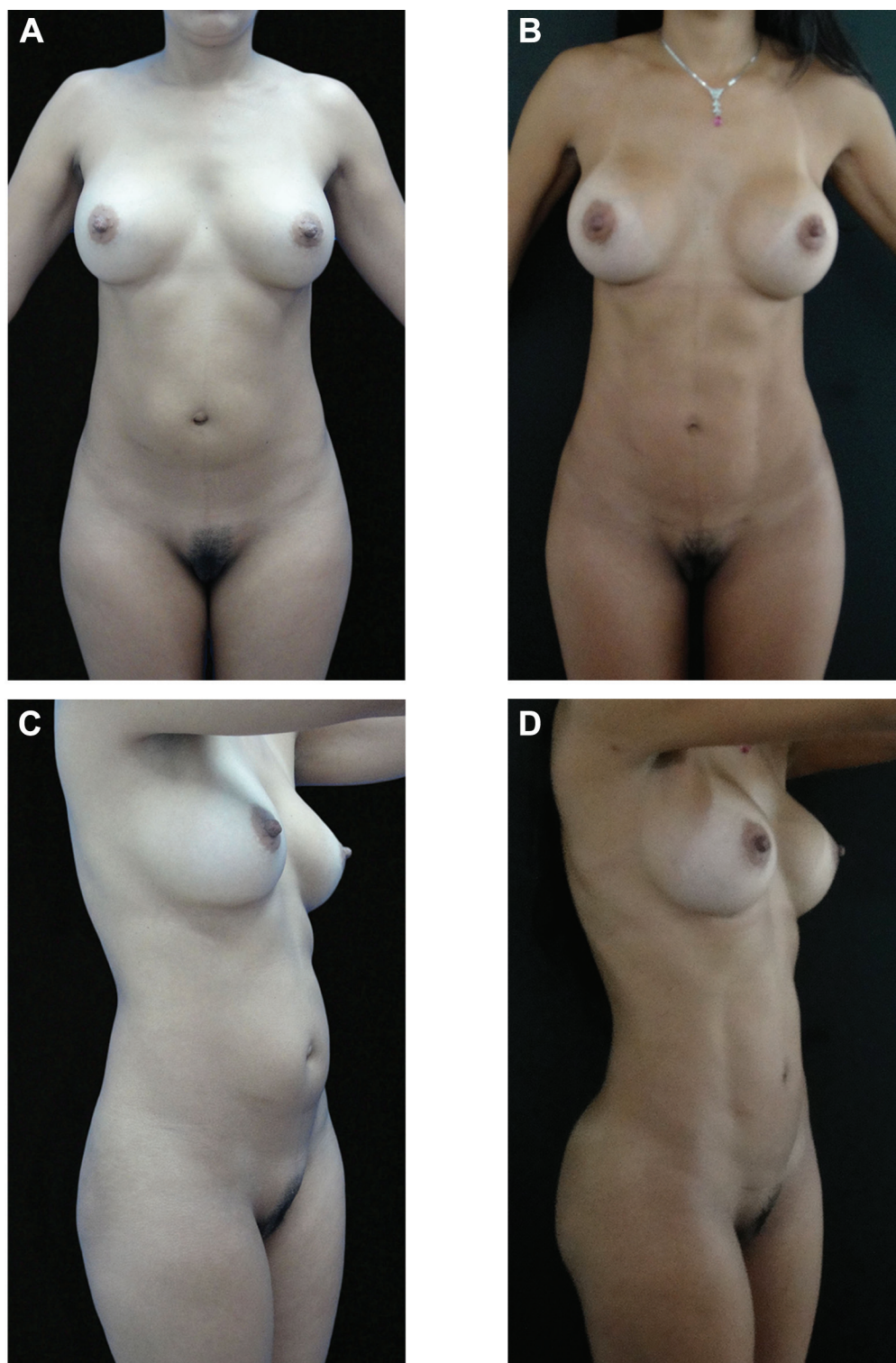


**Figure 6. (continued)** (A, C, E, G, I) This 30-year-old patient presented for dynamic definition mini-abdominoplasty. (B, D, F, H, J) One year after liposuction extraction of approximately 4000 mL in her arms, back, abdomen, hips, and waist. Fat grafting was performed in the buttocks (200 mL on each side). Note the overall change in the contour and the enhanced athletic shape.



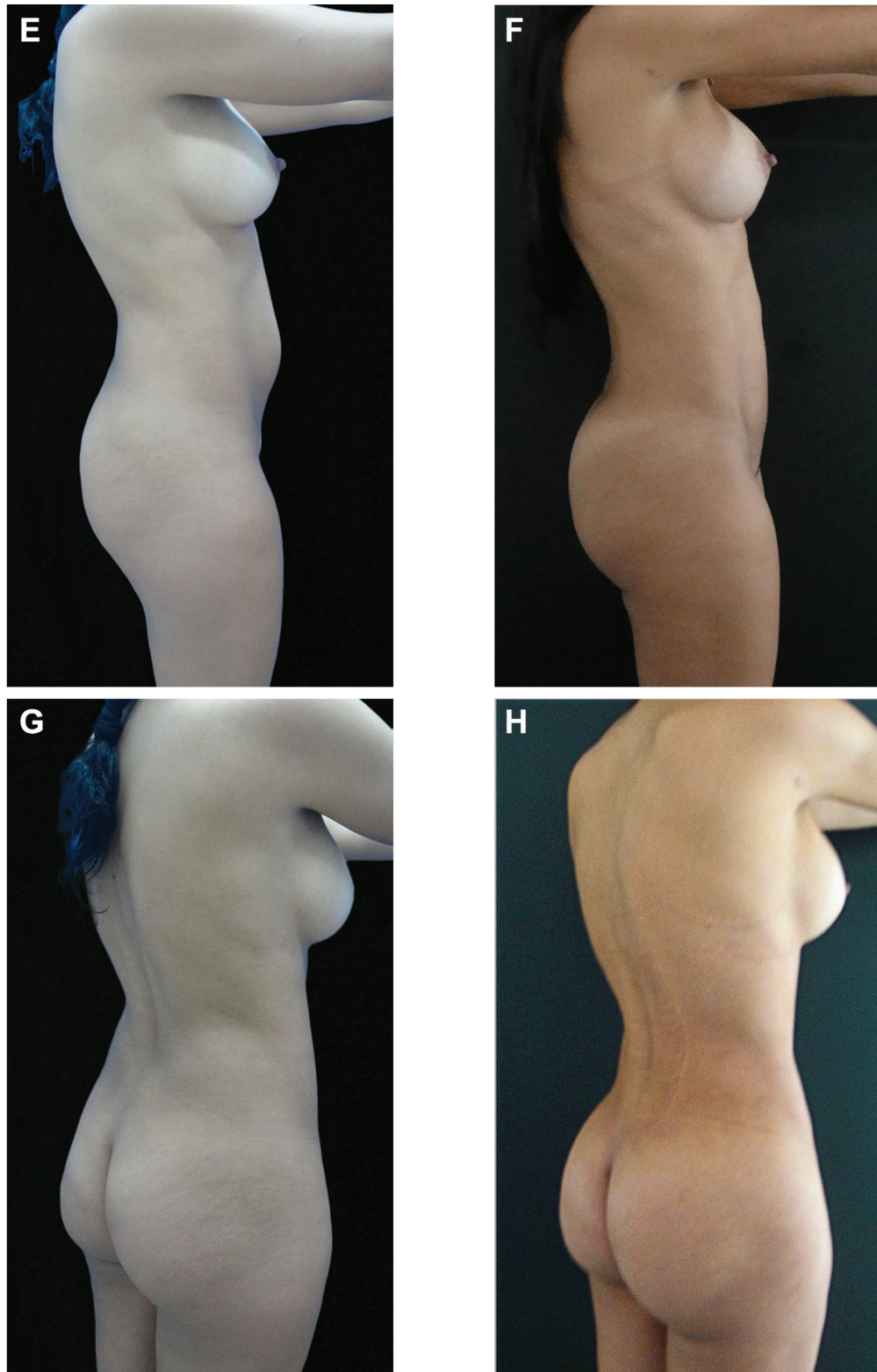


**Figure 6. (continued)** (A, C, E, G, I) This 30-year-old patient presented for dynamic definition mini-abdominoplasty. (B, D, F, H, J) One year after liposuction extraction of approximately 4000 mL in her arms, back, abdomen, hips, and waist. Fat grafting was performed in the buttocks (200 mL on each side). Note the overall change in the contour and the enhanced athletic shape.



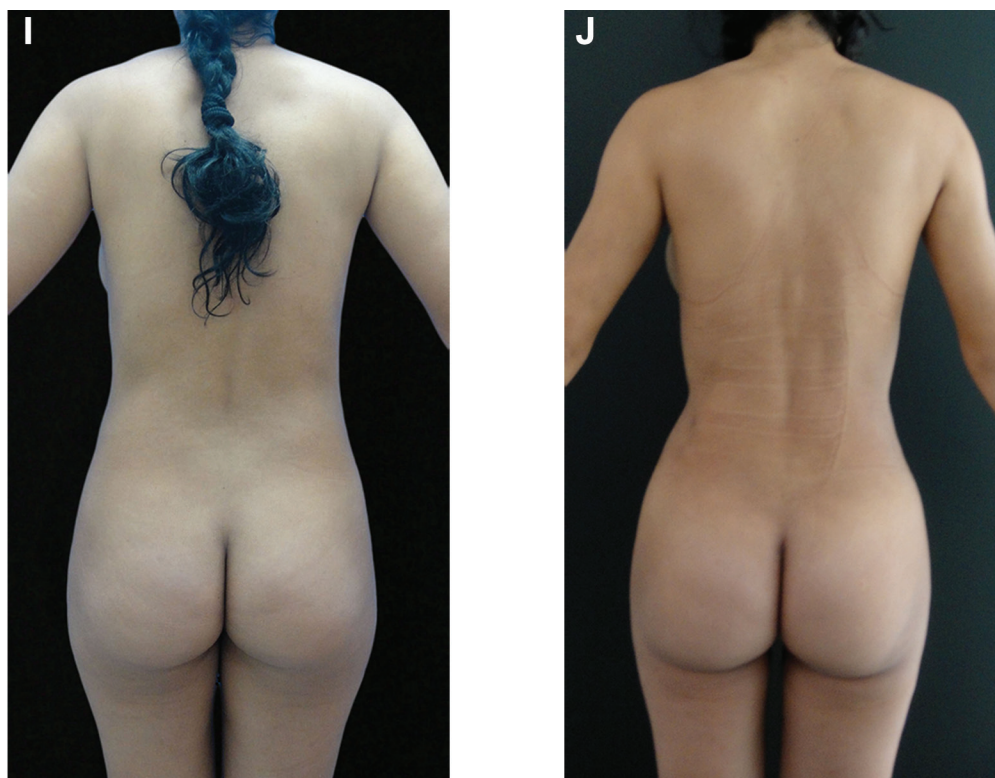
**Figure 7.** (A, C, E, G, I) This 36-year-old woman presented for dynamic definition mini-abdominoplasty. The central anterior abdominal redundancy indicates rectus abdominis muscle diastasis. (B, D, F, H, J) Three months after liposuction extraction of about 3800 mL in her arms, back, abdomen, hips, and waist. Fat grafting was also performed in the buttocks (250 mL on each side). Note the improved abdominal contour and definition. Breast implant exchange and mastopexy by internal capsulorrhaphy were also performed on this patient.



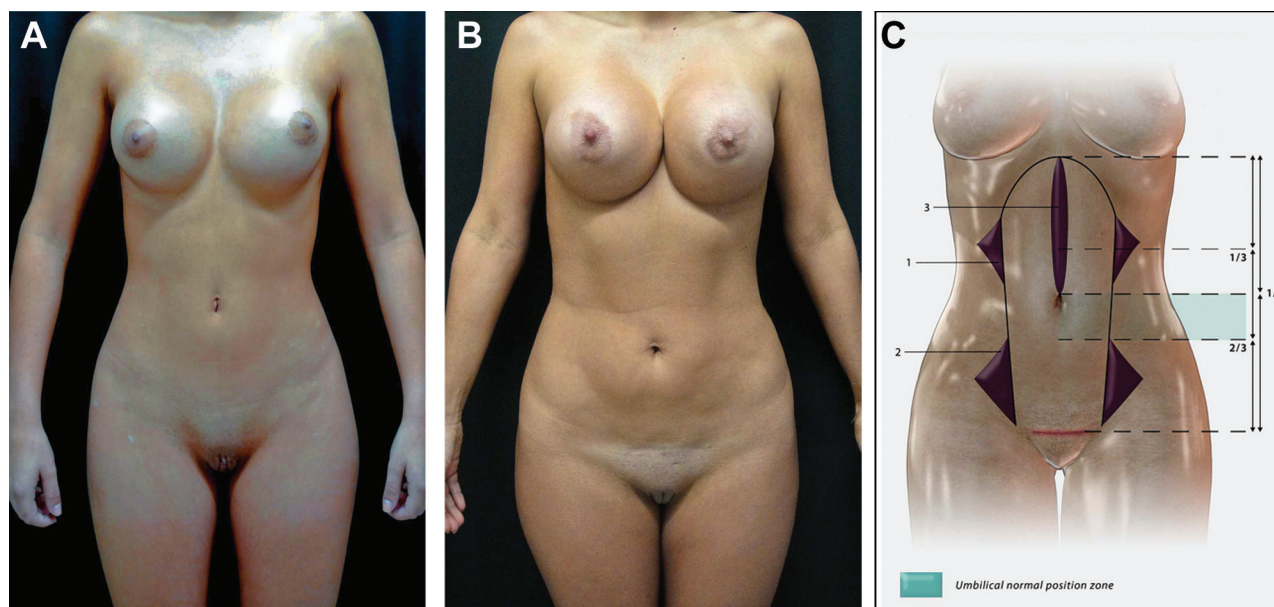


**Figure 7. (continued)** (A, C, E, G, I) This 36-year-old woman presented for dynamic definition mini-abdominoplasty. The central anterior abdominal redundancy indicates rectus abdominis muscle diastasis. (B, D, F, H, J) Three months after liposuction extraction of about 3800 mL in her arms, back, abdomen, hips, and waist. Fat grafting was also performed in the buttocks (250 mL on each side). Note the improved abdominal contour and definition. Breast implant exchange and mastopexy by internal capsulorrhaphy were also performed on this patient.





**Figure 7. (continued)** (A, C, E, G, I) This 36-year-old woman presented for dynamic definition mini-abdominoplasty. The central anterior abdominal redundancy indicates rectus abdominis muscle diastasis. (B, D, F, H, J) Three months after liposuction extraction of about 3800 mL in her arms, back, abdomen, hips, and waist. Fat grafting was also performed in the buttocks (250 mL on each side). Note the improved abdominal contour and definition. Breast implant exchange and mastopexy by internal capsulorrhaphy were also performed on this patient.



**Figure 8.** A youthful abdomen may be achieved by a higher (A) rather than lower (B) location of the umbilicus. (C) Lines 1, 2, and 3 denote negative spaces where deep and superficial liposuction must be performed to achieve more athletic-looking and slimmer results. The blue zone, located between the midpoint and the junction of the middle and lower thirds, would be the ideal location for the navel.

## Funding

The author received no financial support for the research, authorship, and publication of this article.

## REFERENCES

- Demars and Marx. In: Voloir P, ed. *Opérations plastiques aus-aponévrotiques sur la paroi abdominale antérieure*. Vol 1. Paris, France: Thèse; 1960:25.
- Kelly HA. Report of gynecological cases. *Johns Hopkins Med J*. 1899;10:197.
- Illouz YG. A new safe and aesthetic approach to suction abdominoplasty. *Aesthetic Plast Surg*. 1992;16(3):237-245.
- Avelar J. Fat suction versus abdominoplasty. *Aesthetic Plast Surg*. 1985;9(4):265-275.
- Avelar JM. Abdominoplasty combined with lipoplasty without panniculus undermining: abdominolipoplasty—a safe technique. *Clin Plast Surg*. 2006;33:79-90.
- Saldanha OR, Azevedo SF, Delboni PS, Saldanha Filho OR, Saldanha CB, Uribe LH. Lipoabdominoplasty: the Saldanha technique. *Clin Plast Surg*. 2010;37(3):469-481.
- Stewart KJ, Stewart DA, Coghlan B, Harrison DH, Jones BM, Waterhouse N. Complications of 278 consecutive abdominoplasties. *J Plast Reconstr Aesthetic Surg*. 2006;59(11):1152-1155.
- 2012 American Society for Aesthetic Plastic Surgery National Cosmetic Surgery Data Bank Statistics. Available at: <http://www.surgery.org/sites/default/files/ASAPS-2012-Stats.pdf>.
- Greminger RF. The mini-abdominoplasty. *Plast Reconstr Surg*. 1987;79(3):356-365.
- Wilkinson TS. Mini-abdominoplasty. *Plast Reconstr Surg*. 1988;82(5):917-918.
- Cooper MA. Mini-abdominoplasty. *Plast Reconstr Surg*. 1988;81(3):473-475.
- Ferraro GA, Rossano F, Miccoli A, Contaldo L, D'Andrea F. Modified mini-abdominoplasty: navel transposition and horizontal residual scar. *Aesthetic Plast Surg*. 2007;31(6):663-665.
- Nguyen TT, Kim KA, Young RB. Tumescence mini abdominoplasty. *Ann Plast Surg*. 1997;38(3):209-212.
- Shestak KC. Marriage abdominoplasty expands the mini-abdominoplasty concept. *Plast Reconstr Surg*. 1999;103(3):1020-1031; discussion 1032-1035.
- Walgenbach KJ, Shestak KC. "Marriage" abdominoplasty: body contouring with limited scars combining mini-abdominoplasty and liposuction. *Clin Plast Surg*. 2004;31(4):571-581.
- Kumari R, Jaisankar TJ, Thappa DM. A clinical study of skin changes in pregnancy. *Indian J Dermatol Venereol Leprol*. 2007;73(2):141.
- Muallem MM, Rubeiz NG. Physiological and biological skin changes in pregnancy. *Clin Dermatol*. 2006;24(2):80-83.
- Schmutz JL. Physiological skin changes during pregnancy. *Presse Med*. 2003;32(38):1806-1808.
- Gasperoni C. Suction-assisted lipectomy of the subdermal liposuction fat layer: subdermal liposuction. *Ann Int Symp Recent Adv Plast Surg*. 1990;90:477.
- Matarasso A. Liposuction as an adjunct to a full abdominoplasty revisited. *Plast Reconstr Surg*. 2000;106(5):1197-1202; discussion 1203-1205.
- Cimino WW, Bond LJ. Physics of ultrasound surgery using tissue fragmentation: part I. *Ultrasound Med Biol*. 1996;22:89-100.
- Cimino WW. The physics of soft tissue fragmentation using ultrasonic frequency vibrations of metal probes. *Clin Plast Surg*. 1999;26:447-461.
- Cimino WW. Ultrasound surgery: power quantification and efficiency optimization. *Aesthetic Surg J*. 2001;21:233-240.
- De Souza Pinto EB, Indaburo PE, Da Costa Muniz A, et al. Superficial liposuction: body contouring. *Clin Plast Surg*. 1996;23(4):529-548.
- De Souza Pinto EB. Morpho-histological analysis of abdominal skin as related to liposuction. *Aesthetic Plast Surg*. 1997;21(3):153-158.
- Fodor PB, Cimino WW, Watson JP, Tahernia A. Suction-assisted lipoplasty: physics, optimization, and clinical verification. *Aesthetic Surg J*. 2005;25:234-246.
- Gasparotti M, Lewis CM. *Superficial Liposculpture: Manual of Technique*. New York, NY: Springer-Verlag; 1990.
- Gasparotti M. Superficial liposuction for flaccid skin patients. *Ann Int Symp Recent Adv Plast Surg*. 1990;90:441.
- Gasparotti M. Superficial liposuction: a new application of the technique for aged and flaccid skin. *Aesthetic Plast Surg*. 1992;16:141-153.
- Gasperoni C. MALL liposuction: the natural evolution of subdermal superficial liposuction. *Aesthetic Plast Surg*. 1994;18:253-257.
- Gasperoni C. Rationale of subdermal superficial liposuction related to the anatomy of subcutaneous fat and the superficial fascial system. *Aesthetic Plast Surg*. 1995;19:13-20.
- Gasperoni C. Subdermal liposuction. *Aesthetic Plast Surg*. 1990;14:137-142.
- Jewell ML, Fodor PB, de Souza Pinto EB, Al Shammari MA. Clinical application of VASER-assisted lipoplasty: a pilot clinical study. *Aesthetic Surg J*. 2002;22:131-146.
- Rochrich RJ, Beran SJ, Di Spaltro F, et al. Extending the role of liposuction in body contouring with ultrasound-assisted liposuction. *Plast Reconstr Surg*. 1998;101:1090-1102.
- Rochrich RJ, Beran SJ, Kenkel JM. *Ultrasound-Assisted Liposuction*. St Louis, MO: Quality Medical Publishing; 1998.
- Schefflan M, Tazi H. Ultrasonically assisted body contouring. *Aesthetic Surg J*. 1996;16:117-122.
- Scuderi N, Paolini G, Grippaudo FR, Tenna S. Comparative evaluation of traditional, ultrasonic, and pneumatic assisted lipoplasty: analysis of local and systemic effects, efficacy, and costs of these methods. *Aesthetic Plast Surg*. 2000;24:395-400.
- Troilius C. Ultrasound-assisted lipoplasty: is it really safe? *Aesthetic Surg J*. 1999;23:307-311.
- Zocchi ML. Ultrasound-assisted lipoplasty. *Adv Plast Reconstr Surg*. 1995;11:197-221.
- Zocchi ML. Ultrasound-assisted lipoplasty: technical refinements and clinical evaluations. *Clin Plast Surg*. 1996;23:575-598.

41. Zukowski ML. Ultrasound-assisted lipoplasty learning curve. *Aesthetic Surg J*. 1998;18:104-110.
42. Hoyos AE, Millard JA. Vaser-assisted high definition lipoplasty. *Aesthetic Surg J*. 2007;27:594-604.
43. Hoyos AE. High definition liposculpture. Paper presented at: XIII International Course of Plastic Surgery; October 9, 2003; Bucaramanga, Colombia.
44. Hoyos AE, Perez ME. Arm dynamic definition by liposculpture and fat grafting. *Aesthetic Surg J*. 2012;32(8):974-987.
45. Bircoll M. Cosmetic breast augmentation utilizing autologous fat and liposuction techniques. *Plast Reconstr Surg*. 1987;79(2):267-271.
46. Cardenas-Camarena L, Lacouture AM, Tobar-Losada A. Combined gluteoplasty: liposuction and lipoinjection. *Plast Reconstr Surg*. 1999;104(5):1524-1531.
47. Carraway JH. Hand rejuvenation with structural fat grafting by Sydney R. Coleman. *Plast Reconstr Surg*. 2002;110(7):1745-1747.
48. De Blacam C, Momoh AO, Colakoglu S, Tobias AM, Lee BT. Evaluation of clinical outcomes and aesthetic results after autologous fat grafting for contour deformities of the reconstructed breast. *Plast Reconstr Surg*. 2011;128(5):411e-418e.
49. De Pedroza LV. Fat transplantation to the buttocks and legs for aesthetic enhancement or correction of deformities: long-term results of large volumes of fat transplant. *Dermatol Surg*. 2000;26(12):1145-1149.
50. Fournier P. Fat grafting: my technique. *Dermatol Surg*. 2000;26:1117.
51. Guisantes E, Fontdevila J, Rodríguez G. Autologous fat grafting for unaesthetic scars correction. *Ann Plast Surg*. 2012;69(5):550-554.
52. Hudson DA, Lambert EV, Bloch CE. Site selection for fat autotransplantation: some observations. *Aesthetic Plast Surg*. 1990;14:195.
53. Illouz YG, Sterodimas A. Autologous fat transplantation to the breast: a personal technique with 25 years of experience. *Aesthetic Plast Surg*. 2009;33(5):706-715.
54. Pap GS. Autologous fat grafting for body contouring. *Plast Reconstr Surg*. 1998;101(4):1167-1168.
55. Pereira LH, Radwansky H. Fat grafting of the buttock and lower limbs. *Aesthetic Plast Surg*. 1996;20:409.
56. Klein JA. Tumescence technique for regional anesthesia permits lidocaine doses of 35 mg/kg for liposuction. *J Dermatol Surg Oncol*. 1990;16(3):248-263.
57. Decarle DW, Durfee RB. The Pfannenstiel incision for cesarean section. *West J Surg Obstet Gynecol*. 1948;56(6):360-364.
58. Bruekers SE, van der Lei B, Tan TL, Luijendijk RW, Stevens HP. "Scarless" umbilicoplasty: a new umbilicoplasty technique and a review of the English language literature. *Ann Plast Surg*. 2009;63(1):15-20.
59. Franco D, Medeiros J, Farias C, Franco T. Umbilical reconstruction for patients with a midline scar. *Aesthetic Plast Surg*. 2006;30(5):595-598.
60. Lee MJ, Mustoe TA. Simplified technique for creating a youthful umbilicus in abdominoplasty. *Plast Reconstr Surg*. 2002;109(6):2136-2140.
61. Badran HA. Histopathologic changes of autogenous fat grafting in albino rats. *Plast Reconstr Surg*. 1997;99(2):607.
62. Carpaneda CA, Ribeiro MT. Percentage graft viability versus injected volume in adipose auto transplants. *Aesthetic Plast Surg*. 1994;18:17-19.
63. Coleman SR. Structural fat grafting. *Plast Reconstr Surg*. 2005;115(6):1777-1778.
64. Ersek RA. Transplantation of purified autologous fat: a 3-year follow-up is disappointing. *Plast Reconstr Surg*. 1991;87:219-227.
65. Guerrero-Santos J. Autologous fat grafting for body contouring. *Clin Plast Surg*. 1996;23(4):619-631.
66. Lewis CM. The current status of autologous fat grafting. *Aesthetic Plast Surg*. 1993;17:109-112.
67. Yanai A. Lipoinjection. *Plast Reconstr Surg*. 2003;111(1):528.
68. Baran CN, Celebioglu S, Sensoz O, Ulusoy G, Civelek B, Ortak T. The behavior of fat graft in recipient areas with enhanced vascularity. *Plast Reconstr Surg*. 2002;109:1646.
69. Chajchir A. Fat injection: long-term follow-up. *Aesthetic Plast Surg*. 1996;20:291-296.
70. Guerrero-Santos J. Long term survival of free fat grafts in muscle: an experimental study in rats. *Aesthetic Plast Surg*. 1996;20:403-408.
71. Sommer B, Sattler G. Current concepts of graft survival: histology of aspirated adipose tissue and review of the literature. *Dermatol Surg*. 2000;26:1159-1166.